

## Basic Science and Treatment Options for Articular Cartilage Injuries

Paul B. Lewis, MS<sup>1</sup>

L. Pearce McCarty, III, MD<sup>2</sup>

Richard W. Kang, BS<sup>3</sup>

Brian J. Cole, MD, MBA<sup>4</sup>

Articular cartilage injuries can produce significant musculoskeletal morbidity for both young and active aging patient populations. The complex and highly specialized composition of normal hyaline cartilage makes treatment of focal chondral injuries a formidable challenge for the basic scientist, surgeon, and physical therapist. The current array of surgical treatment options offers palliative, reparative, and restorative treatment strategies. Palliative options include simple arthroscopic debridement. Reparative strategies utilize marrow stimulation techniques to induce formation of fibrocartilage within the chondral defect. Restorative tactics attempt to replace damaged cartilage with hyaline or hyaline-like tissue using osteochondral or chondrocyte transplantation. Furthermore, while treatment success is obviously dependent on good surgical selection and technique, the importance of sound, compliant postoperative rehabilitation cannot be understated. The purpose of this article is to review the basic science of articular cartilage, current treatment options available, and outline the clinical decision making involved when using these procedures by presenting the algorithm used at our institution for treating focal cartilage lesions. *J Orthop Sports Phys Ther* 2006;36(10):717-727. doi:10.2519/jospt.2006.2175

**Key Words:** arthritis, basic science, cartilage, knee, treatment options

Articular cartilage defects have been recognized as a cause of significant morbidity for more than 200 years.<sup>29</sup> Articular cartilage defects can be limited to the superficial layers of cartilage (ie, partial thickness) or can extend to the underlying subchondral plate (ie, full-thickness). Certain defects, such as those resulting from osteochondritis dissecans, may actually be osteochondral in nature, with involvement of subchondral bone. Partial-thickness defects are not necessarily associated with significant clinical problems.<sup>37</sup> They are important to consider, however, as it is thought that they may be the first step in the progression to a full-thickness defect. Full-thickness chondral defects are more commonly symptomatic, resulting in recurrent effusions, activity-related pain, and compromise of quality of life. The intrinsic repair capacity of such defects remains limited to production of fibrocartilage, a repair tissue that is biologically inferior to native hyaline cartilage tissue.<sup>7,20,29</sup> When symptomatic, small full-thickness injuries may be successfully treated with minimally invasive techniques designed to permit the efflux of marrow elements into the

defect, resulting in fibrocartilage formation. Large defects may respond poorly to such techniques, however, and may therefore require more sophisticated strategies.<sup>1,14</sup>

The ultimate success of cartilage restoration procedures depends upon preoperative selection and planning, surgical experience and decision-making, and strict compliance to postoperative rehabilitation protocols. Given the importance of postoperative rehabilitation, the success of cartilage restoration procedures falls in the hands of the physical therapist-patient relationship as much as it does in the surgeon's preoperative selection and planning.

The goals of any cartilage restoration procedure are to (1) replace damaged cartilage with hyaline or hyaline-like tissue, (2) reduce a patient's symptoms, (3) return a patient to a productive level of function, and (4) allow for future treatment options should they become necessary. The lattermost of these goals reflects a central tenet of cartilage restoration procedures: preservation of existing cartilage so that future treatment options and rehabilitations are available, should the current procedure fail.

The purpose of this article is to review currently accepted surgical options for chondral injury and

<sup>1</sup> Student, Rush University Medical College, Chicago, IL.

<sup>2</sup> Attending Physician, Sports and Orthopaedic Specialists, Minneapolis, MN.

<sup>3</sup> Student, Rush University Medical College, Chicago, IL.

<sup>4</sup> Assistant Professor, Sports Medicine Division, Rush University Medical Center, Chicago, IL.

Address correspondence to Brian J. Cole, Assistant Professor, Sports Medicine Division, Rush University Medical Center, 1725 West Harrison Street, Suite 1063, Chicago, IL 60612. E-mail: bcole@ushortho.com

provide the treatment algorithm established and used at our institution. The understanding and use of any cartilage restoration procedure, however, begins with an appreciation for the native cartilage and its natural response to injury. Detailed discussion of rehabilitation protocols, with rationale for progression, is beyond the scope of this paper.

## Basic Science

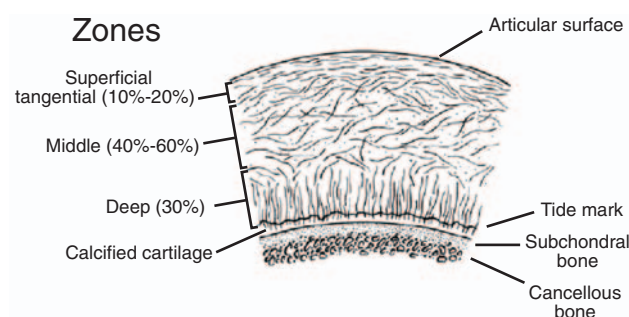
The articular cartilage of the knee is hyaline in nature and measures from 2 to 4 mm in thickness. Hyaline cartilage is composed of both a solid and fluid phase. The interaction of these 2 phases provides specific biphasic material properties, described as viscoelastic, which signifies that the load-bearing properties of the tissue are both position and rate dependent.

The solid phase of cartilage, comprising 95% of the tissue by volume, is composed principally of collagen (10% to 20% of total weight) and, to a lesser amount, proteoglycans (4% to 7% of the total weight).<sup>9</sup> These together make up the extracellular matrix of articular cartilage. The collagen is principally type II collagen; however, types V, VI, IX, X, XI, XII, and XIV are also found in cartilage, but still collectively less than the amount of type II collagen.<sup>9</sup> Collagen interacts to form large fibrils that trap large proteoglycan aggregates.

The proteoglycan of interest is aggrecan. Its protein backbone has both chondroitin sulfate and keratan sulfate groups attached to it. Large molecules of aggrecan are formed through the interaction of aggrecan and a hyaluronic acid chain. These complexes (hyaluronic acid and aggrecans) are found throughout the collagen matrix. Due to the numerous negatively charged sulfated groups, the complexes electrostatically interact with cations, ultimately forming ion-dipole interactions with water. Water comprises up to 65% to 80% of the total weight of the tissue.<sup>9</sup> Interaction of water with proteoglycans provides a swollen, hydrated tissue that resists compression.

The resident cell type of cartilage is the chondrocyte. Chondrocytes are sparsely distributed throughout the matrix in both longitudinal and vertical fashion. Collectively, they provide just 2% of the total volume of articular cartilage.<sup>1</sup> Chondrocytes maintain the extracellular matrix surrounding them (just previously described) and are thus imperative for maintaining healthy cartilage, whether in native or transplanted tissue. Chondrocyte survival depends on physical stresses, electrostatic forces, and local paracrine effects.<sup>10,34</sup>

Articular, hyaline cartilage is organized histologically into 4 specialized layers, each providing unique characteristics (ie, fluid dynamics, composition, and architecture)<sup>11</sup> and structure. These layers, from superficial to deep, include the superficial (tangential



**FIGURE 1.** Hyaline cartilage architecture. From Alford and Cole, *The American Journal of Sports Medicine* (33,3) pp. 443-60. Copyright 2003 by Sage Publications, reprinted with permission of Sage Publications, Inc.

zone), middle (transitional zone), deep (radial zone), and the calcified layer (Figure 1). The superficial layer protects deeper layers from the shear stresses involved with articulation. For this role, the lamina splendens has collagen fibers (primarily type II and IX collagen) packed tightly together and organized parallel to the articular surface. Unlike other layers, the chondrocytes of the superficial layer are relatively flattened. The integrity of this layer is imperative in protecting and maintaining the deeper layers.

Immediately deep to the superficial zone is the transition zone, which provides an anatomic and functional bridge between the superficial and deep zones. The collagen is organized obliquely and chondrocytes become more spherical in this layer. Functionally, this layer is the first line of resistance to the compressive forces. Bulk resistance to compression is found in the deep zone, where the collagen is organized perpendicular to the articulating surface. Anchoring the collagen-rich layers above it to the subchondral bone, the calcified layer plays an integral role in securing the cartilage to the bone. Between the deep layer and calcified layer is the tidemark. The tidemark provides the deepest resistance to shear and appropriately has collagen fibers orientated parallel with the articular surface. The individual contributions of these distinct layers provide for the superior loading and minimal friction characteristics of the tissue and a primary reason for our difficulty in repairing or replacing this complex tissue.<sup>9,10</sup>

## Chondral Lesions: ICRS Grading

The grading of articular cartilage lesions is important for research documentation purposes and to permit clinicians to convey information between one another in an accurate manner. Determination of grade is performed at the time of arthroscopy via direct observation and instrumented palpation of the lesion. While several classifications have been described in the literature,<sup>3,31,51</sup> the senior author finds the grading system established by the International Cartilage Repair Society (ICRS)<sup>8</sup> to be the most

complete. The ICRS established this grading system with the idea that it can be used as a universal language for communication of cartilage lesions among surgeons and other healthcare professionals. The ICRS grading system is based on the depth of the lesion and the degree to which subchondral bone is involved (Figure 2).

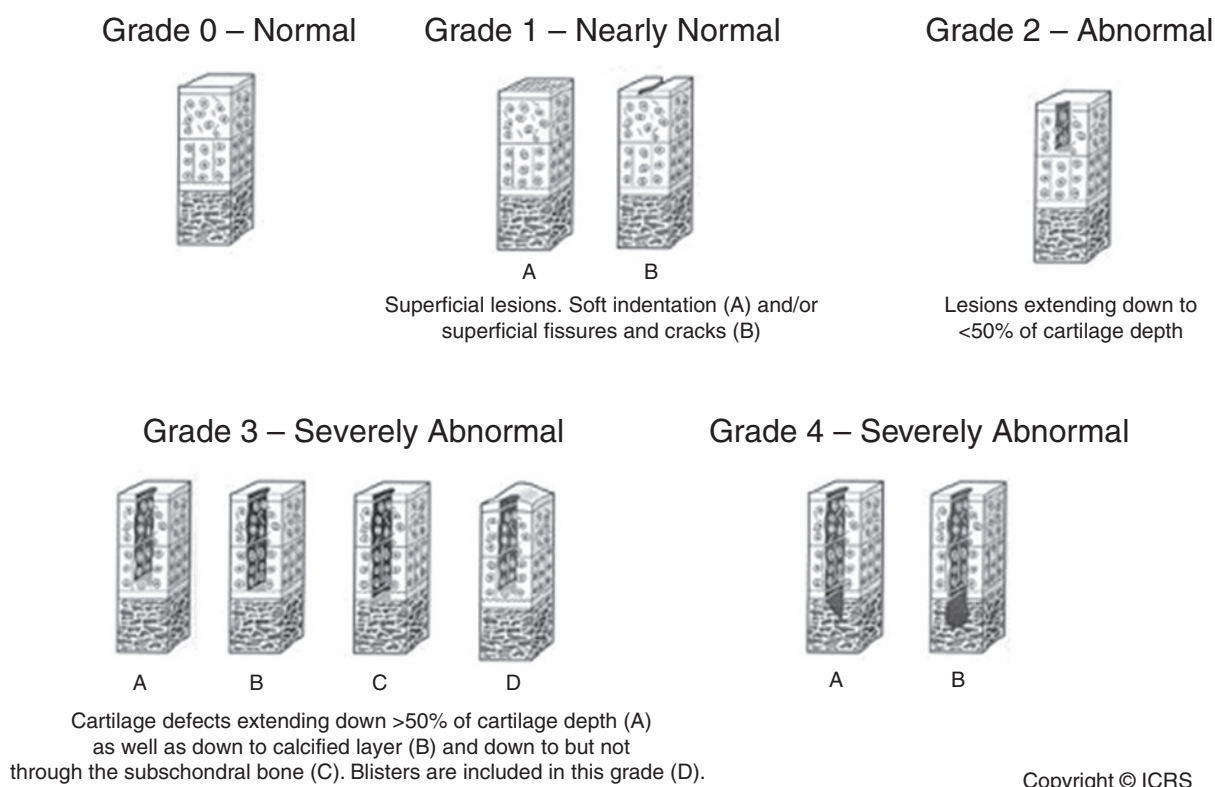
## Epidemiology

The incidence and prevalence of chondral lesions is difficult to gauge both because lesions may be silent and physicians may lack experience in diagnosing chondral injury. A number of retrospective studies, however, have provided estimates of prevalence. In a limited review of 993 knee arthroscopies, Aroen and colleagues<sup>2</sup> found that 11% of patients had a full-thickness lesion of the cartilage. Hjellev and colleagues<sup>28</sup> reported a 5% prevalence of grade III or IV lesions after a review of 1000 arthroscopies. In a larger study reviewing 31 516 knee arthroscopies, Curl and colleagues<sup>15</sup> found that 19 827 (63%) of patients had a chondral lesion. Moreover, of the arthroscopies reviewed, grade III lesions were found in 12 921 (41%) patients and grade IV lesions in 5988 (19%) patients.

While the natural history of chondral lesions has not been clearly delineated, there is evidence to

support the idea that an asymptomatic lesion can progress into a symptomatic one, or that a superficial lesion can progress to a full-thickness defect. Messner and colleagues<sup>41</sup> followed unipolar, unicompartamental lesions after surgical debridement and found progressive joint space narrowing on radiographic examination. Furthermore, when considering the potential for a chondral lesion to progress, a patient must be assessed for angular limb malalignment, ligamentous instability, and meniscus deficiency, all of which can contribute to this progression. Malalignment of the knee markedly increases focal contact pressures in articular cartilage, thus potentiating increased mechanical wear in the regions affected.

Complete meniscectomy has also been established as a contributor to osteoarthritic changes in the knee.<sup>33</sup> Even partial resection of the meniscus has been shown to increase stress in the involved compartment.<sup>33,41</sup> Cicuttini and colleagues<sup>12</sup> found a 6.5% volumetric loss of cartilage per year after meniscectomy. Finally, ligamentous instability alters the biomechanics of the moving joint and can introduce increasing shear forces on the articular cartilage. It is possible that even with successful ligamentous repair an associated untreated cartilage lesion will progress to a symptomatic problem for the patient.<sup>16,36</sup>



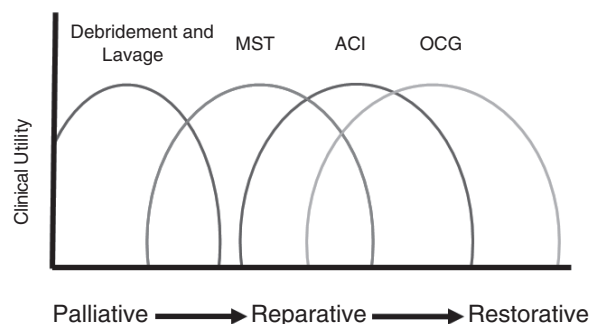
**FIGURE 2.** ICRS Grading. The International Cartilage Repair Society grading system for normal and abnormal articular cartilage. Printed with kind permission from the International Cartilage Repair Society.

## Response to Injury

Articular cartilage has limited ability for intrinsic repair secondary to its relatively avascular nature and an apparent lack of chondrocyte division and migration around and into a given zone of injury. Even superficial damage is thought to violate the highly sensitive anatomical and biochemical interdependence of the articular cartilage zones and instigate the development of more significant damage. The early stages of superficial damage (or partial-thickness injuries) are marked by cellular insult. The injured chondrocytes have impaired metabolic capacity and thus cannot maintain the normal proteoglycan concentration. This leads to other alterations in the tissue, such as increased tissue hydration and fibrillar disorganization of the collagen.<sup>35,37,38,47</sup> Together, this ultimately translates, biomechanically, into increased force transmission to the subchondral bone. Reflexively, the subchondral bone experiences a reduction in compliance, which causes impact loads to be more readily transmitted to the damaged cartilage. To combat this process, chondrocytes can only respond by proliferating and increasing the production of matrix molecules at the site of injury. This new matrix, however, typically fails to restore the native surface.<sup>37</sup> The cyclic degeneration described here is thought to contribute to the progression of partial-thickness injuries.<sup>46</sup>

Full-thickness injuries that penetrate subchondral bone and allow influx of pluripotent marrow elements theoretically have a higher potential for intrinsic repair.<sup>24</sup> The localized bleeding created by disrupting the subchondral bone provides for hematoma formation and a primitive healing response.<sup>20</sup> Migrating mesenchymal stem cells produce type I collagen fibers to fill the full-thickness defect with fibrocartilage. Fibrocartilage falls short in providing the necessary functions needed of articular cartilage. Compared to the functional characteristics of native hyaline cartilage a fibrocartilage matrix has inferior stiffness, resilience, and wear qualities.<sup>48</sup>

The absence of meaningful intrinsic healing capacity in articular cartilage, coupled with recent advances in orthopaedic biologic science, has led to the development of multiple operative strategies for addressing focal chondral defects. While individuals with low physical demands may accept palliative therapy in the form of arthroscopic debridement as a temporizing solution, younger individuals with high physical demands require a careful, stepwise approach that includes sophisticated reparative and restorative strategies. Reparative strategies utilize marrow stimulation techniques to induce formation of fibrocartilage. Restorative tactics attempt to replace damaged cartilage with hyaline or hyaline-like tissue using osteochondral or chondrocyte transplantation.



**FIGURE 3.** Treatment objectives versus clinical utility. Overlapping treatment options range from palliative to restorative objectives. Each procedure has a maximal clinical utility and specific indication. Abbreviations: ACI, autologous chondrocyte implantation; MST, marrow stimulation (microfracture); OCG, osteochondral grafting (autograft or allograft).

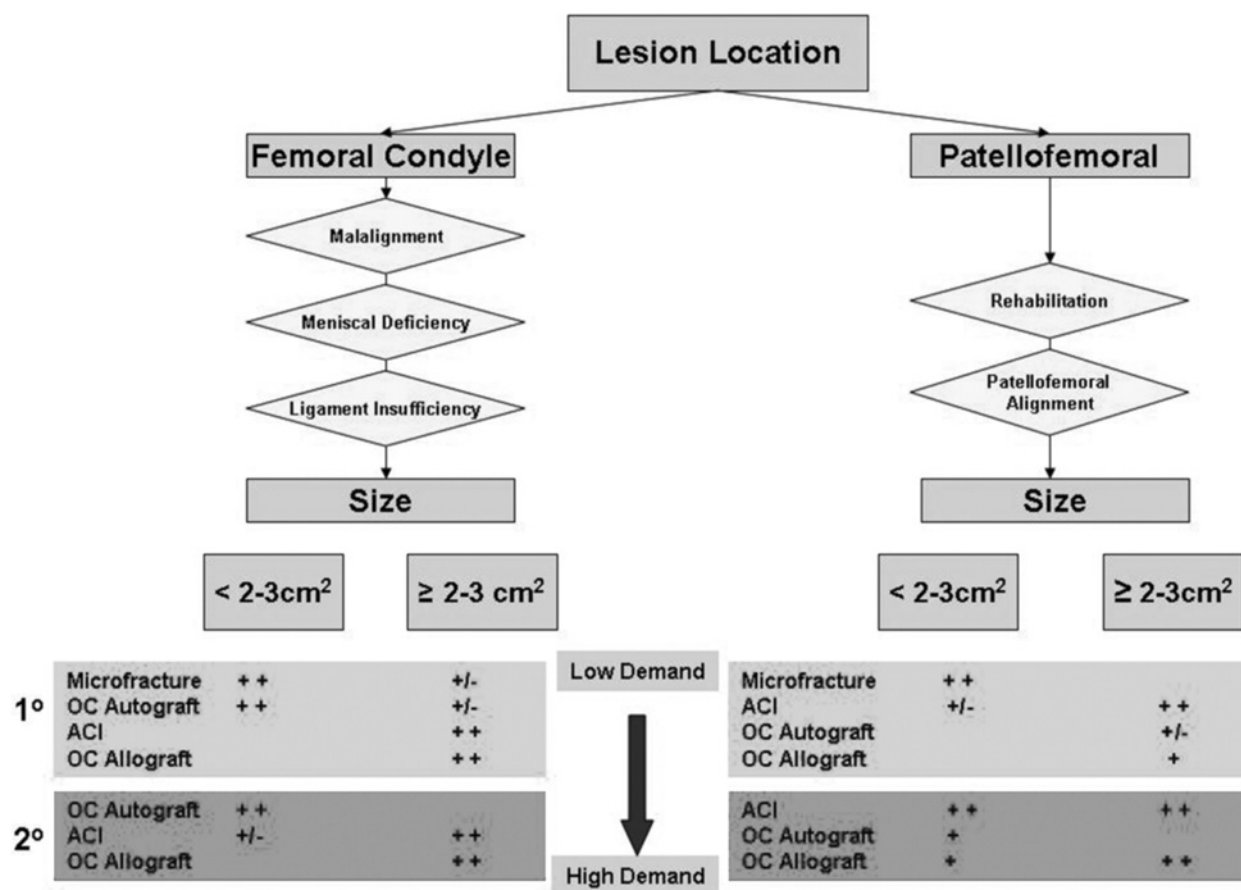
## Cartilage Restoration Techniques and Considerations

To understand the specific indications of available cartilage restoration procedures, a basic familiarity with the techniques themselves is required. There is often overlap in the clinical utility of procedures used to address chondral defects (Figure 3). To facilitate selection of the appropriate procedure for the appropriate patient, our institution has established and follows a specific treatment algorithm that considers lesion size, depth, patient age, and success or failure of previous treatments (Figure 4). A detailed explanation of the specific indications for each procedure is described later. Finally, treatment of cartilage defects must also take into account the simultaneous or staged correction of limb malalignment, ligamentous instability, or meniscus deficiency. Neglect of such concomitant pathologies can predispose any operative strategy to early failure.

## Arthroscopic Lavage and Debridement

The goal of lavage and debridement is to reduce the inflammation and mechanical irritation within a given joint. Debridement can include smoothing of fibrillated articular or meniscal surfaces, shaving of motion-limiting osteophytes, and removal of inflamed synovium. Lavage of the joint is thought to reduce synovitis and pain by washing fragments of cartilage<sup>17</sup> and calcium phosphate crystals from the knee.<sup>56</sup> While not successful in providing a durable benefit in globally arthritic knees, this strategy may offer significant symptomatic relief for select patients.<sup>45</sup> Harwin<sup>27</sup> found through retrospective review that lavage and debridement were of most value in patients with specific localized mechanical symptoms, minimal malalignment, and no history of previous surgery. Additionally, in separate prospective trials, both, debridement<sup>40</sup> and lavage<sup>30</sup> resulted in significant





**FIGURE 4.** Treatment algorithm. A careful, stepwise strategy should be followed when treating chondral defects. For a femoral condyle lesion, malalignment of the knee, meniscal deficiency, and ligamentous injuries must be properly addressed before or concomitantly with the treatment of the lesion. Subsequently, options to address the lesion itself depend on the size of the lesion as well as the intended activity level of the patient. Similar considerations need to be taken into account for patellofemoral lesions. 1°, first line cartilage repair treatment; 2°, second line should primary or first line treatment fail. Abbreviations: ACI, autologous chondrocyte implantation; OC, osteochondral.

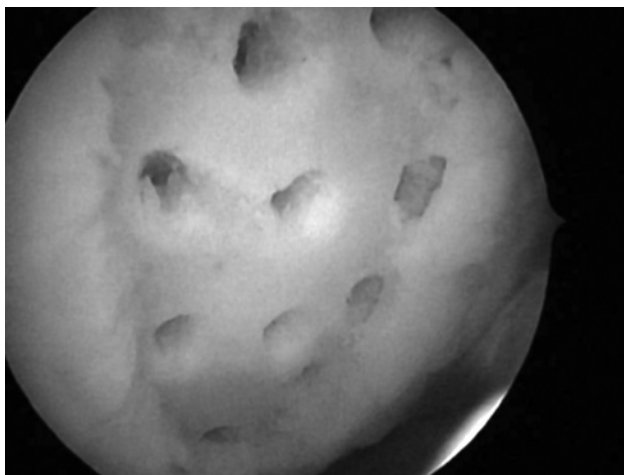
improvements in knee pain when compared to nonoperatively treated cohorts. This procedure represents a reasonable first-line palliative treatment for individuals with low physical demands, but likely does not offer a long-term solution.

### Microfracture

The reparative technique that finds the most support in the literature is that of microfracture. The surgical objective of microfracture is the controlled perforation of the subchondral bone plate to permit the efflux of pluripotent marrow elements (eg, mesenchymal stem cells and growth factors) into a chondral defect.<sup>55</sup> The recruitment of such elements into the defect site leads to the production of a fibrin “superclot” that evolves and remodels over a period of 12 to 16 months into a fibrocartilage mosaic repair tissue.<sup>18</sup> It is important to note that the fibrocartilage repair tissue is predominantly type I collagen and, as previously discussed, does not resist compression and

shear loads as predictably as the native hyaline cartilage.

In the experience of the senior author, indications for microfracture include small (<2 cm<sup>2</sup>) unipolar, focal grade III or IV lesions without bone loss that are well-shouldered by normal articular cartilage. The initial step during microfracture is to debride the lesion of all remaining cartilage and scar tissue and establish a well-defined edge, or shoulder, between the bed of the defect and neighboring hyaline cartilage. Doing so provides a mechanical environment that reduces shear and compressive forces on the lesion, thus allowing development of the fibrocartilage repair tissue in a relatively protected environment. A surgical awl is then used to perforate the subchondral plate, creating holes spaced 2 to 3 mm apart and working from the periphery to the center of the defect (Figure 5). The appropriate depth of penetration (2-4 mm) is confirmed by reducing arthroscopic fluid inflow and visually assessing the efflux of blood and marrow from the holes.<sup>18</sup>



**FIGURE 5.** Microfracture. Perforations into the subchondral bone (measuring 2 to 4 mm in depth) are created with a surgical awl and spaced 2 to 3 mm apart. One should avoid gross disruption of the subchondral plate.

Following microfracture, compliance with the postoperative rehabilitation protocol is essential to the outcome of the procedure. After a well-executed procedure and compliance with postoperative protocol, this procedure can provide symptomatic relief and functional improvement inexpensively without eliminating other treatment options should they be needed.

An 11-year follow-up by Steadman and colleagues<sup>54</sup> reported significant subjective improvement with respect to the Tegner, Western Ontario, and McMaster Universities' Osteoarthritis Index, Lysholm, and Short Form-36 scores. Self-assessed improvement remained considerable (80% of patients) at 7-year follow-up. A more recent report on a series of 109 patients, mean follow-up of 72 months (36-120 months) by Gobbi et al<sup>23</sup> reported both subjective and objective (ie, Lysholm and Tegner scores) improvements at follow-up as compared to preoperative scores.

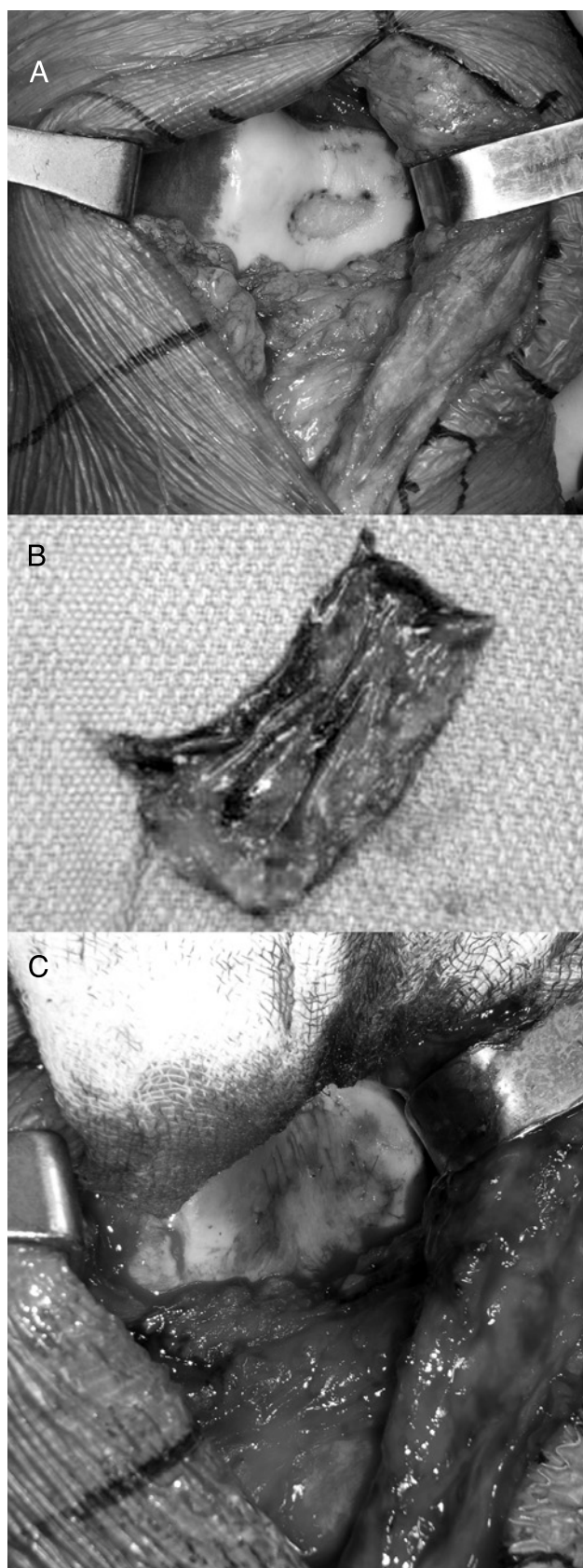
### Autologous Chondrocyte Implantation

Autologous chondrocyte implantation (ACI) is a cartilage restorative procedure in which a concentrated solution of autologous chondrocytes is implanted into a defect with the goal of restoring hyaline cartilage to the injured area. ACI is often reserved for those patients that have failed traditional first-line treatments such as debridement, marrow stimulation, and osteochondral autograft techniques. The ideal indications are symptomatic, unipolar, well-contained defects (2-10 cm<sup>2</sup>) that do not involve violation of the subchondral plate. Contraindications include bipolar lesions (grade II or higher on the opposing surface) and lesions that involve significant bone loss. Malalignment, ligament instability, and meniscus deficiency are relative contraindications that must be corrected simultaneously with, or prior to, ACI.

The first stage of the procedure involves arthroscopic evaluation of the lesion (eg, lesion boundaries, depth, and bone loss) and biopsy of normal articular cartilage (200-300 mg) for in vitro tissue expansion.<sup>42</sup> The cartilage biopsy is taken from a minimally load-bearing region of the knee joint, such as the superomedial edge of the trochlea<sup>22</sup> or the lateral edge of the intercondylar notch.<sup>1</sup> The second stage, implantation, normally occurs 6 weeks to 18 months after graft harvest. The defect is debrided of scar tissue and fibrocartilage back to healthy hyaline borders (Figure 6A). Care is taken to avoid penetration of the subchondral plate to prevent mixing of marrow elements and cultured chondrocytes. A periosteal patch is then taken from the anterior tibia and sutured over the defect to create a biologically hospitable, watertight envelope into which autologous chondrocytes can be implanted (Figures 6B and 6C).

Patient adherence to the postoperative rehabilitation protocol is essential to the success of the procedure. The rehabilitation protocol for this procedure reflects the 3 phases of natural chondrocyte maturation (proliferative phase, matrix production phase, and maturation phase).<sup>22,43,39</sup> Most important to the early phases of recovery is use of continuous passive motion (6-8 hours per day at 1 cycle per minute) to assist in cellular orientation and adhesion prevention. Protected weight bearing is indicated for the first 4 to 6 weeks as matrix production is stimulated through load bearing. It is important to note, however, that the graft must be protected from mechanical overload during this time to protect the delicate periosteal patch. The patient is slowly advanced to full weight bearing to stimulate the maturation phase of cartilage. The general complication rate surrounding the use of periosteal flaps in ACI approaches 20%. Mechanical symptoms, such as catching and clicking, if they occur in the 3- to 6-month period postoperatively, usually suggest flap hypertrophy and resolve with time. If patients remain symptomatic, arthroscopic evaluation of the repaired lesion and debridement of the hypertrophied portion of the flap may be required. If the flap is found to be completely avulsed, then a revision cartilage restoration procedure may be indicated.

The most favorable results of ACI have been reported for isolated femoral lesions, with slightly less favorable results reported for patellar lesions. Peterson et al<sup>51</sup> initially published two 9-year follow-up results with only 62% good to excellent results for ACI of patellar lesions as compared to 89% for femoral lesions. As more attention has been given to performing concomitant tibial tubercle anteromedialization in the case of central and lateral patellofemoral lesions,<sup>4</sup> results for these defects have improved, with 85% of patients with good to excellent results.<sup>51</sup> The senior author (B.J.C.) has reported



**FIGURE 6.** Autologous Chondrocyte Implantation. (A) The lesion is debrided to make a well-shouldered defect. (B) A periosteal patch retrieved from the proximal medial tibia. (C) The periosteal patch is sewn to neighboring healthy articular cartilage to create a watertight envelope into which autologous chondrocytes will be injected.

on treatment of 103 femoral condyle defects, with complete subjective satisfaction reported in 79.3% of patients with a mean follow-up of 27.5 months.<sup>13</sup> Furthermore, recent reports have shown success with ACI in treatment of the talus,<sup>32</sup> proximal humerus,<sup>52</sup> and elbow.<sup>6</sup>

### Osteochondral Grafting

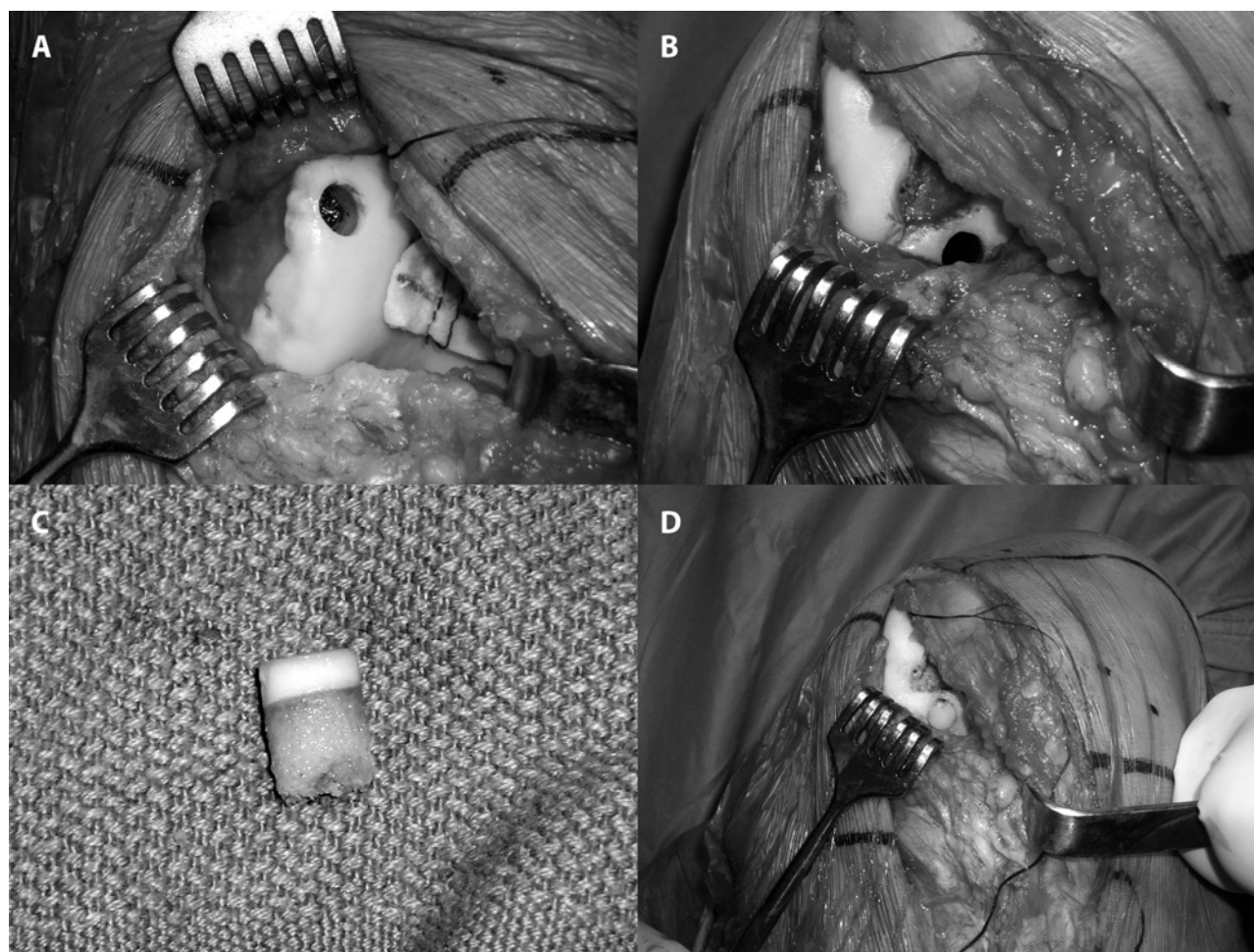
*Osteochondral Autograft Transfer* Restoration of injured cartilage can also be accomplished through osteochondral autograft or allograft transplantation, particularly in cases that involve loss of both cartilage and underlying bone. Osteochondral autograft is most clearly indicated for a symptomatic, unipolar lesion of the distal femoral condyle in a nondegenerative joint that has proper limb alignment, as well as ligamentous stability and meniscal competence. As with other cartilage procedures, malalignment, ligamentous instability, and meniscal deficiency serve as relative contraindications and must be corrected either simultaneously or in staged fashion with the osteochondral transfer. While large lesions have been treated with osteochondral autograft transfer, the ideal lesion size is 1 to 2 cm in diameter. This limitation exists because of donor site considerations, including limited graft availability and operative morbidity (limitations not seen with the use of osteochondral allografts).

The objective of osteochondral autograft transfer is to take healthy articular cartilage from a minimally load-bearing region of the knee and transfer it to the damaged region of the same knee in a single procedure. In contrast to ACI, this technique involves a single procedure, and transfers an entire osteochondral plug, permitting one to address chondral lesions that include underlying bone loss.

Osteochondral autograft transfer can be performed using an all-arthroscopic technique or by utilizing a small arthrotomy. The donor plug is harvested from a minimally load-bearing site, typically the femoral intercondylar notch for small-diameter plugs or from the edge of the lateral femoral condyle for plugs of larger diameter. Simonian et al<sup>53</sup> compared the contact pressures experienced by these 2 potential donor sites and found that there was significant contact pressure of unknown clinical significance in both of them. Garretson et al<sup>21</sup> investigated 2 alternative locations for donation, medial trochlea, and distal lateral trochlear ridge. Both of these sites demonstrated relatively lower contact pressures. Donor site selection remains dependent in part on the location of the lesion.

The graft is harvested through the use of standardized, commercially available graft harvesters. The harvester is placed perpendicular to the donor site and advanced to 12 to 15 mm into the cartilage and underlying subchondral bone. The harvester is then





**FIGURE 7.** Osteochondral autograft transfer (OATs). (A) A circular osteochondral plug is harvested from a minimally load-bearing surface of the affected knee. (B) The defect is prepared to match the diameter of the harvested autologous osteochondral plug (lower lesion is the prepared lesion, the superior lesion is to be repaired with a concomitant autologous chondrocyte implantation procedure). (C) An example of a harvested autologous osteochondral plug prior to implantation. (D) The osteochondral plug is seated flush with surrounding cartilage.

rotated to facilitate extraction of the donor osteochondral plug (Figure 7A).

Preparation of the recipient tunnel is accomplished in a similar fashion, with the exception that the hole is created at a depth of 2 mm less than the donor graft (Figure 7B). During tunnel preparation and graft harvesting, particular attention needs to be given to keeping the harvester perpendicular to the articular surface. After the recipient tunnel is prepared, the donor graft (Figure 7C) is press-fit atraumatically and initially left slightly proud. The plug is then seated with the use of a tamp, such that it lies flush with the surfaces of the neighboring cartilage (Figure 7D).

The postoperative rehabilitation protocol utilizes both passive and active motion to augment graft incorporation. Protective weight bearing is advised for the same reason. Graft healing is assessed through clinical and radiographic evaluation. With evidence of full integration the patient is advanced to full-weight-bearing and weight-bearing exercises.

The results of autologous osteochondral grafting in the knee have been excellent and show promise for

treatment of lesions in other joints. In a review of their 10-year experience with osteochondral autografting to treat full-thickness lesions of weight-bearing joints, Hangody and Fules<sup>25</sup> report a good or excellent result in 79% of patients when treating patellofemoral defects, 87% when treating tibial plateau lesions, and 92% when treating isolated defects of the femoral condyle. Emerging reports of osteochondral allograft use in other joints have been promising and include the treatment of the talus,<sup>26</sup> femoral head,<sup>25</sup> and elbow.<sup>5</sup>

*Osteochondral Allograft Transplantation* In contrast to osteochondral autograft transfer, osteochondral allograft transplantation relies upon tissue taken from cadaveric donors rather than from the patient's own knee. The benefits of allografting include elimination of donor site morbidity and the ability to provide fully formed articular cartilage without specific limitation with respect to defect size. The drawbacks to the procedure are graft availability, cell viability (highly dependent upon graft preparation and preservation technique), immunogenicity, and risk of disease transmission. The indications for osteochondral allograft-



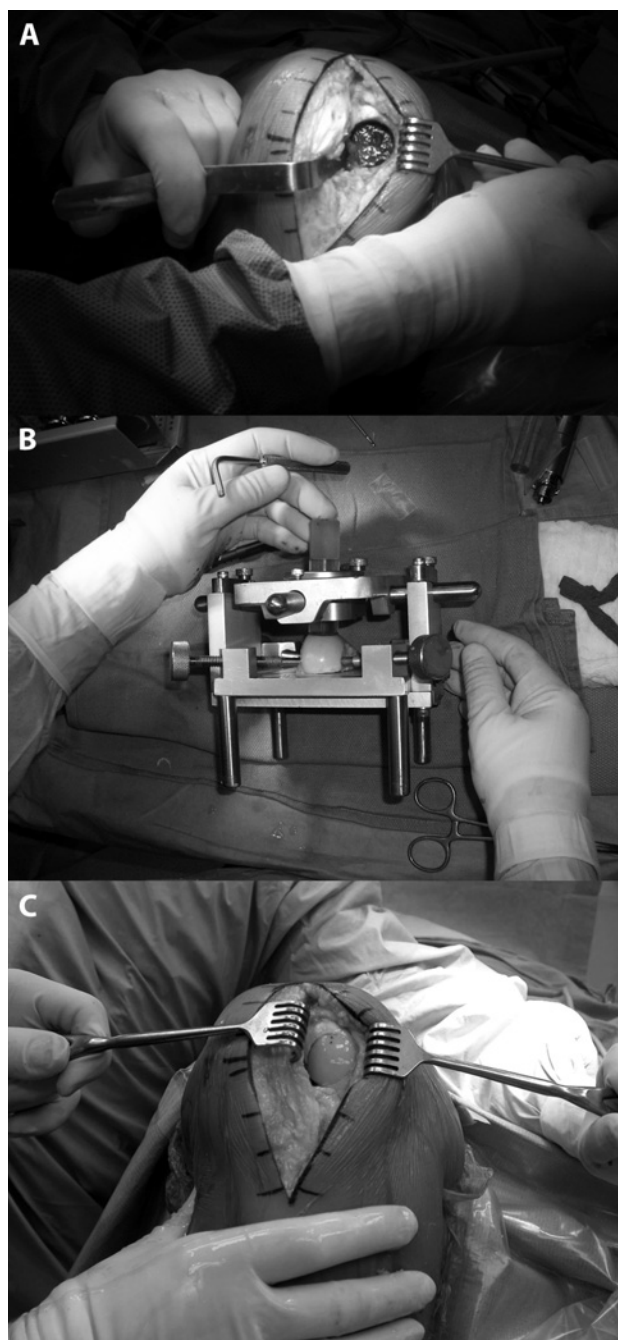
ing are similar to those for osteochondral autograft transfer, with the exception of defect size. Given the unrestricted transplantable tissue volume that osteochondral allografting offers, it is often reserved for larger lesions (2-3 cm<sup>2</sup> or greater) that have significant bone loss.

Most transplanted grafts are considered “fresh tissue grafts,” meaning they are procured within 12 hours of the donor’s death, processed within 14 days of procurement, and transplanted within 28 days without the need for deep-frozen storage. The main sources of graft immunogenicity are blood or bone marrow elements of the graft. To minimize potential immune reaction, these elements are washed from the donor tissue at the time of procurement. Immune reactions that do occur between the host and allograft tissue are thought to be self-limited and do not limit graft success.<sup>19</sup> The chance of disease transmission is nearly eliminated through strict donor screening, sterile procurement and processing, and storage in antibiotic solution.

For osteochondral allograft transplantation, when a size- and side-matched graft becomes available, patients are notified and quickly scheduled for surgery. Availability of osteochondral graft tissue varies with institution and geographic location. To perform the actual procedure, exposure of the lesion to be grafted is accomplished through a mini-arthrotomy. The diameter of the defect is matched to a cannulated sizing cylinder from a commercially available instrumentation system. The cylinder is centered over the lesion and held perpendicular to the cartilage surface, permitting precise central placement of a guide pin. Using a cannulated reaming device, the lesion is then reamed to a depth of 8 to 10 mm, followed by adjunctive drilling with a small diameter bit into the base of the lesion, with the idea of creating multiple vascular access channels that will facilitate graft incorporation (Figure 8A). The depth of the recipient socket is such that it provides enough apposition to permit an adequate press fit, but minimizes the volume of immunogenic donor bone implanted.

To harvest the donor osteochondral plug (the allograft tissue), typically a full hemicondyle is secured into a commercially available allograft workstation. The curvature of the harvest site is matched to the curvature of the patient’s recipient socket through topographic marking. The 12 o’clock position of the graft is marked on the donor tissue and a Cloward drill bit is used to harvest the donor osteochondral plug (Figure 8B).

Before implantation, the allograft is washed with pulsatile lavage to eliminate residual marrow elements, further decreasing the chance of disease transmission and graft immunogenicity. The graft is then press-fit into the socket with careful attention to plug orientation. Once set, the plug is gently im-



**FIGURE 8.** Osteochondral allograft transplantation. (A) The lesion site is prepared to receive the allograft plug using a measured cylindrical reamer. (B) The osteochondral allograft plug is cut from the donor condyle using specially designed cutting jig. (C) The osteochondral plug is implanted such that it matches the contour of the host condyle and is flush with the surrounding articular surface.

pacted into the socket with the use of an oversized tamp. The final product is a well-secured, well-seated plug that matches the contour of the neighboring host articular cartilage (Figure 8C).

Postoperative rehabilitation includes limited weight bearing for a minimum of 8 weeks and early use of continuous passive motion (6-8 hours per day at 1 cycle per minute). This protocol provides mechanical stimulation for chondrocyte growth and orientation, while preventing premature overload of the graft that

can result in subchondral collapse. High-impact sports are not recommended after allografting because of the risk of collapsing the subchondral bone and possible graft deterioration.<sup>49</sup>

The outcome of osteochondral allografting has generally been best for younger patients with isolated traumatic lesions or osteochondritis dissecans. In 1985, McDermott and colleagues<sup>39</sup> reported on the outcome of the first 100 osteochondral allograft procedures, in which only 56% of patients demonstrated a good or excellent result at a mean of 3.8 years follow-up. Results have since improved, benefiting from more careful patient selection and advances in allograft processing procedures, surgical technique, and postoperative rehabilitation. Current evidence would suggest that between 75% and 85% of patients undergoing osteochondral allografting can expect subjective improvement.<sup>1</sup> Proper patient selection remains paramount for the success of osteochondral allografting as well as the other cartilage restoration procedures.

## SUMMARY

The variegated structure of hyaline cartilage makes treatment of cartilage injuries and, in particular, repair or restoration of full-thickness chondral defects problematic for the basic scientist, surgeon, and physical therapist alike. Lesions may remain clinically silent for indeterminate periods of time, making accurate characterization of incidence and prevalence difficult. Furthermore, the propensity for superficial lesions to progress to full-thickness lesions is poorly understood.

Recent advances in the science of cartilage restoration on both basic science and clinical levels have led to the development of a variety of palliative, reparative, and restorative treatment strategies. Palliative treatment options, such as arthroscopic debridement, may be appropriate as first-line treatment for certain patient populations with low physical demand but likely do not represent viable strategies for individuals with high physical demand. Reparative techniques, such as microfracture and certain restorative techniques as osteochondral autograft transfer, represent durable treatment options for higher-demand individuals with small, contained chondral lesions. More sophisticated restorative strategies, such as autologous chondrocyte implantation (ACI) and osteochondral allograft transplantation, are appropriate for higher-demand individuals with larger chondral lesions or those with significant involvement of the subchondral plate. Additionally, coexisting pathologies, such as angular malalignment, ligamentous instability, and meniscal pathology, must be addressed in either simultaneous or staged fashion to avoid early treatment failure of chondral lesions. Finally, as the majority of these operative techniques rely upon a time-dependent maturation and remodeling of repair

tissue for their success, the importance of proper postoperative rehabilitation cannot be overemphasized.

## REFERENCES

1. Alford JW, Cole BJ. Cartilage restoration, part 1: basic science, historical perspective, patient evaluation, and treatment options. *Am J Sports Med.* 2005;33:295-306.
2. Aroen A, Loken S, Heir S, et al. Articular cartilage lesions in 993 consecutive knee arthroscopies. *Am J Sports Med.* 2004;32:211-215.
3. Bauer M, Jackson RW. Chondral lesions of the femoral condyles: a system of arthroscopic classification. *Arthroscopy.* 1988;4:97-102.
4. Beck PR, Thomas AL, Farr J, Lewis PB, Cole BJ. Patellofemoral contact forces following anteromedialization of the tibial tubercle. *Arthroscopy.* In press.
5. Bradley JP, Petrie RS. Osteochondritis dissecans of the humeral capitellum. Diagnosis and treatment. *Clin Sports Med.* 2001;20:565-590.
6. Brittberg M, Peterson L, Sjogren-Jansson E, Tallheden T, Lindahl A. Articular cartilage engineering with autologous chondrocytes. *Clin Orthop.* 1996;270-283.
7. Brittberg M, Peterson L, Sjogren-Jansson E, Tallheden T, Lindahl A. Articular cartilage engineering with autologous chondrocyte transplantation. A review of recent developments. *J Bone Joint Surg Am.* 2003;85-A Suppl 3:109-115.
8. Brittberg M, Winalski CS. Evaluation of cartilage injuries and repair. *J Bone Joint Surg Am.* 2003;85-A Suppl 2:58-69.
9. Buckwalter JA, Hunziker EB. Articular cartilage biology and morphology. In: Mow VC, Ratcliffe A, eds. *Structure and Function of Articular Cartilage.* Boca Raton, FL: CRC Press, Inc; 1993.
10. Buckwalter JA, Mankin HJ. Articular cartilage: tissue design and chondrocyte-matrix interactions. *Instr Course Lect.* 1998;47:477-486.
11. Buckwalter JA, Hunziker EB, Rosenberg LC, Coutts RD, Adams M, Eyre D. Articular cartilage: composition and structure. In: Woo SLY, Buckwalter JA, eds. *Injury and Repair of the Musculoskeletal Soft Tissues.* Park Ridge, IL: American Academy of Orthopaedic Surgeons; 1988:405-425.
12. Cicuttini FM, Forbes A, Yuanyuan W, Rush G, Stuckey SL. Rate of knee cartilage loss after partial meniscectomy. *J Rheumatol.* 2002;29:1954-1956.
13. Cole BJ, Fox JA, Nho SJ, et al. Prospective evaluation of autologous chondrocyte implantation. *Annual Meeting of the American Academy of Orthopaedic Surgeons.* New Orleans, LA: American Academy of Orthopaedic Surgeons; 2003.
14. Convery FR, Akeson WH, Keown GH. The repair of large osteochondral defects. An experimental study in horses. *Clin Orthop Relat Res.* 1972;82:253-262.
15. Curl WW, Krome J, Gordon ES, Rushing J, Smith BP, Poehling GG. Cartilage injuries: a review of 31,516 knee arthroscopies. *Arthroscopy.* 1997;13:456-460.
16. Duchow J, Hess T, Kohn D. Primary stability of press-fit-implanted osteochondral grafts. Influence of graft size, repeated insertion, and harvesting technique. *Am J Sports Med.* 2000;28:24-27.
17. Evans CH, Mazzocchi RA, Nelson DD, Rubash HE. Experimental arthritis induced by intraarticular injection of allogenic cartilaginous particles into rabbit knees. *Arthritis Rheum.* 1984;27:200-207.

18. Freedman KB, Nho SJ, Cole BJ. Marrow stimulating technique to augment meniscus repair. *Arthroscopy*. 2003;19:794-798.
19. Friedlaender GE, Strong DM, Sell KW. Studies on the antigenicity of bone. II. Donor-specific anti-HLA antibodies in human recipients of freeze-dried allografts. *J Bone Joint Surg Am*. 1984;66:107-112.
20. Furukawa T, Eyre DR, Koide S, Glimcher MJ. Biochemical studies on repair cartilage resurfacing experimental defects in the rabbit knee. *J Bone Joint Surg Am*. 1980;62:79-89.
21. Garretson RB, 3rd, Katolik LI, Verma N, Beck PR, Bach BR, Cole BJ. Contact pressure at osteochondral donor sites in the patellofemoral joint. *Am J Sports Med*. 2004;32:967-974.
22. Gill TJ. The role of the microfracture technique in the treatment of full-thickness chondral injuries. *Oper Tech Sports Med*. 2000;8:138-140.
23. Gobbi A, Nunag P, Malinowski K. Treatment of full thickness chondral lesions of the knee with microfracture in a group of athletes. *Knee Surg Sports Traumatol Arthrosc*. 2005;13:213-221.
24. Goldberg VM, Caplan AI. Biologic restoration of articular surfaces. *Instr Course Lect*. 1999;48:623-627.
25. Hangody L, Fules P. Autologous osteochondral mosaicplasty for the treatment of full-thickness defects of weight-bearing joints: ten years of experimental and clinical experience. *J Bone Joint Surg Am*. 2003;85-A Suppl 2:25-32.
26. Hangody L, Kish G, Modis L, et al. Mosaicplasty for the treatment of osteochondritis dissecans of the talus: two to seven year results in 36 patients. *Foot Ankle Int*. 2001;22:552-558.
27. Harwin SF. Arthroscopic debridement for osteoarthritis of the knee: predictors of patient satisfaction. *Arthroscopy*. 1999;15:142-146.
28. Hjelle K, Solheim E, Strand T, Muri R, Brittberg M. Articular cartilage defects in 1,000 knee arthroscopies. *Arthroscopy*. 2002;18:730-734.
29. Hunter W. Of the structure and disease of articulating cartilages. 1743. *Clin Orthop Relat Res*. 1995;3-6.
30. Ike RW, Arnold WJ, Rothschild EW, Shaw HL. Tidal irrigation versus conservative medical management in patients with osteoarthritis of the knee: a prospective randomized study. Tidal Irrigation Cooperating Group. *J Rheumatol*. 1992;19:772-779.
31. Insall J. Current Concepts Review: patellar pain. *J Bone Joint Surg Am*. 1982;64:147-152.
32. Jurgenson I, Bachmann G, Haas H, et al. Effect of arthroscopic therapy on osteochondritis dissecans of the knee and ankle. *Arthroskopie*. 1998;11:193-199.
33. Lee SJ, Aadalen KJ, Lorenz EP, et al. Tibiofemoral contact mechanics following serial medial meniscectomies in the human cadaveric knee. *American Orthopaedic Society for Sports Medicine Annual Meeting*. Quebec City, Canada: American Orthopaedic Society for Sports Medicine; 2004.
34. Locker M, Kellermann O, Boucquey M, Khun H, Huerre M, Poliard A. Paracrine and autocrine signals promoting full chondrogenic differentiation of a mesoblastic cell line. *J Bone Miner Res*. 2004;19:100-110.
35. Lohmander LS, Dahlberg L, Ryd L, Heinegard D. Increased levels of proteoglycan fragments in knee joint fluid after injury. *Arthritis Rheum*. 1989;32:1434-1442.
36. Mandelbaum BR, Browne JE, Fu F, et al. Articular cartilage lesions of the knee. *Am J Sports Med*. 1998;26:853-861.
37. Mankin HJ. The response of articular cartilage to mechanical injury. *J Bone Joint Surg Am*. 1982;64:460-466.
38. Mankin H, Mow V, Buckwalter J, Iannotti J, Ratcliffe A. Form and function of articular cartilage. In: Simon SR, ed. *Orthopaedic Basic Science*. Rosemont, IL: American Academy of Orthopaedic Surgeons; 1994:1-44.
39. McDermott AG, Langer F, Pritzker KP, Gross AE. Fresh small-fragment osteochondral allografts. Long-term follow-up study on first 100 cases. *Clin Orthop Relat Res*. 1985;96-102.
40. Merchan EC, Galindo E. Arthroscope-guided surgery versus nonoperative treatment for limited degenerative osteoarthritis of the femorotibial joint in patients over 50 years of age: a prospective comparative study. *Arthroscopy*. 1993;9:663-667.
41. Messner K, Maletius W. The long-term prognosis for severe damage to weight-bearing cartilage in the knee: a 14-year clinical and radiographic follow-up in 28 young athletes. *Acta Orthop Scand*. 1996;67:165-168.
42. Minas T. Autologous chondrocyte implantation for focal chondral defects of the knee. *Clin Orthop Relat Res*. 2001;S349-361.
43. Minas T, Chiu R. Autologous chondrocyte implantation. *Am J Knee Surg*. 2000;13:41-50.
44. Minas T, Peterson L. Advanced techniques in autologous chondrocyte transplantation. *Clin Sports Med*. 1999;18:13-44, v-vi.
45. Moseley JB, O'Malley K, Petersen NJ, et al. A controlled trial of arthroscopic surgery for osteoarthritis of the knee. *N Engl J Med*. 2002;347:81-88.
46. Mow VC, Rosenwasser MP. Articular cartilage: biomechanics. In: Woo SLY, Buckwalter J, eds. *Injury and Repair of the Musculoskeletal Soft Tissues*. Park Ridge, IL: American Academy of Orthopaedic Surgeons; 1988:427-463.
47. Mow VC, Setton LA, Ratcliffe A, Howell DS, Buckwalter JS. Structure-function relationships of articular cartilage and the effects of joint instability and trauma on cartilage function. In: Brandt KD, ed. *Cartilage Changes in Osteoarthritis*. Indianapolis, IN: University of Indiana Press; 1990:22-42.
48. Nehrer S, Spector M, Minas T. Histologic analysis of tissue after failed cartilage repair procedures. *Clin Orthop Relat Res*. 1999;149-162.
49. Newman AP. Articular cartilage repair. *Am J Sports Med*. 1998;26:309-324.
50. Outerbridge RE. The etiology of chondromalacia patellae. *J Bone Joint Surg Br*. 1961;43-B:752-757.
51. Peterson L, Minas T, Brittberg M, Nilsson A, Sjogren-Jansson E, Lindahl A. Two- to 9-year outcome after autologous chondrocyte transplantation of the knee. *Clin Orthop Relat Res*. 2000;212-234.
52. Romeo AA, Cole BJ, Mazzocca AD, Fox JA, Freeman KB, Joy E. Autologous chondrocyte repair of an articular defect in the humeral head. *Arthroscopy*. 2002;18:925-929.
53. Simonian PT, Sussmann PS, Wickiewicz TL, Paletta GA, Warren RF. Contact pressures at osteochondral donor sites in the knee. *Am J Sports Med*. 1998;26:491-494.
54. Steadman JR, Briggs KK, Rodrigo JJ, Kocher MS, Gill TJ, Rodkey WG. Outcomes of microfracture for traumatic chondral defects of the knee: average 11-year follow-up. *Arthroscopy*. 2003;19:477-484.
55. Steadman JR, Rodkey WG, Rodrigo JJ. Microfracture: surgical technique and rehabilitation to treat chondral defects. *Clin Orthop Relat Res*. 2001;S362-369.
56. Swan A, Chapman B, Heap P, Seward H, Dieppe P. Submicroscopic crystals in osteoarthritic synovial fluids. *Ann Rheum Dis*. 1994;53:467-470.