



ELSEVIER

Hip Arthroscopy in Athletes

J.W. Thomas Byrd, MD

Arthroscopy has defined numerous elusive causes of disabling hip pain. In the past, athletes were resigned to living within the constraints of their symptoms, often relinquishing their competitive athletic careers. The most common lesions include labral pathology, articular damage, and disruption of the ligamentum teres. Careful clinical assessment is reliable at determining the existence of hip joint pathology, although variable in determining its nature. Arthroscopy is effective at addressing numerous lesions, often allowing successful resumption of the athlete's competitive career. This article details the assessment of hip joint problems in the athlete with numerous illustrative examples highlighting various forms of pathology that can be addressed.

Oper Tech Sports Med 13:24-36 © 2005 Elsevier Inc. All rights reserved.

KEYWORDS hip arthroscopy, athletes

Sports-related injuries to the hip joint have received relatively little attention. This trend is changing, but, until recently, there have been few publications in peer-reviewed journals and the topic has rarely been presented at scientific meetings. This is because of 3 reasons. First, perhaps hip injuries are less common than other joints. Secondly, investigative skills for the hip have been less sophisticated including clinical assessment and imaging studies. Thirdly, there have been fewer interventional methods available to treat the hip including both surgical techniques and conservative modalities and thus there has been little impetus to delve into this unrecognized area.

As the methods of arthroscopy for this joint have become more reliable, a plethora of intra-articular disorders have been uncovered that previously went undiagnosed and largely untreated. Uncovering the existence of these disorders has led to improved clinical assessment skills and improved imaging technology. Thus, more forms of pathology are being recognized and there are now more methods available to treat these injuries.

The indications for hip arthroscopy fall into 2 broad categories. In one, arthroscopy offers an alternative to traditional open techniques previously used for recognized forms of hip pathology such as loose bodies or impinging osteophytes. In the other, arthroscopy offers a method of treatment for disorders that previously went unrecognized including labral tears, chondral injuries, and disruption of the ligamentum

teres. Most athletic injuries fall into this latter category. In the past, athletes were simply resigned to living within the constraints of their symptoms, often ending their competitive careers, diagnosed as a chronic groin injury. Based on the results of arthroscopy among athletes, it is likely that many of these careers could have been rejuvenated with arthroscopic intervention.¹

Assessment

In a study of athletes undergoing arthroscopy, in 60% of the cases, the hip was not recognized as the source of symptoms at the time of initial treatment and were managed for an average of 7 months before the hip was considered as a potential contributing source.¹ The most common preliminary diagnoses were various types of musculotendinous strains (Table 1). Thus, it is prudent to consider the possibility of intra-articular pathology in the differential diagnosis when managing a strain around the hip joint. However, the incidence of intra-articular pathology is probably quite small relative to other extra-articular injuries, and thus it is best to temper the interest for an extensive intra-articular workup for every hip flexor or adductor strain. What is important is thoughtful follow-up and reassessment of injuries, especially when they do not seem to be responding as expected.

A careful history and examination will usually implicate whether the hip is potentially the source of symptoms.² Even if the hip is recognized as the source of the symptoms, there are many causes of hip joint pain that resolve spontaneously with conservative treatment such as capsular sprains, traumatic effusion in absence of structural damage, and other as yet poorly defined entities. Also of note, early diagnosis does

Nashville Sports Medicine and Orthopaedic Center, Nashville, TN.
Address reprint requests to J.W. Thomas Byrd, MD, Nashville Sports Medicine and Orthopaedic Center, 2011 Church Street, Suite 100, Nashville, TN 37203. E-mail: info@nsmoc.com

Table 1 Preliminary Diagnoses (Other Than the Hip)

Hip flexor strain (6)
Lumbar disorder (5)
Unspecified muscle strain (4)
Adductor strain (3)
Iliopsoas tendinitis (2)
Trochanteric bursitis (2)
Hamstring injury (2)
Piriformis syndrome (1)
Sciatica (1)
SI disorder (1)
Stress fracture (1)
Contusion (1)
Malalignment (1)
Do not know (1)

not always mean early intervention. High resolution MRI and gadolinium arthrographic techniques have increased sensitivity and specificity for intra-articular disorders; however, especially at the elite and professional levels, there are many athletes who will demonstrate evidence of pathology simply as a consequence of the cumulative effect of their sport. Thus, the first step in assessing a potential candidate for arthroscopy is often just providing an opportunity see if symptoms will subside with a trial of conservative treatment (Fig 1A-C).

It is important to note that athletes who sustain an intra-articular injury to the hip will often not be disabled by their symptoms. Especially among contact and collision sports, it may be difficult to recount precisely when the injury occurred. Over time, it may become evident only as the symptoms of a seemingly minor injury fail to resolve and increasingly affect performance. In general, mechanical symptoms such as intermittent catching or locking or sharp, stabbing in nature, are more likely to benefit from arthroscopy.³ Those who simply describe aching with activities or aching independent of activities are less likely to respond well.

Hip symptoms are most commonly referred to the anterior groin and may radiate to the medial thigh. However, a very characteristic clinical feature which has been described is the "C-sign."² A patient describing deep interior hip pain will often grip their hand above the greater trochanter with their thumb lying posteriorly and the fingers cupped within the anterior groin. Casually viewed, it may appear that they are describing lateral pain such as the iliotibial band or trochanteric bursa, but characteristically, they are reflecting pain within the hip joint.

On examination, log rolling the leg back and forth is the most specific maneuver for hip pathology since this rotates only the femoral head in relation to the acetabulum and capsule, not stressing any of the surrounding neurovascular or musculotendinous structures. More sensitive examination maneuvers include forced flexion combined with internal rotation or abduction combined with external rotation. Flexion with internal rotation is sometimes referred to as the impingement test.⁴ However, a joint irritated by a variety of conditions will typically be painful with this maneuver, and thus it is not specific for impingement alone. It is postulated

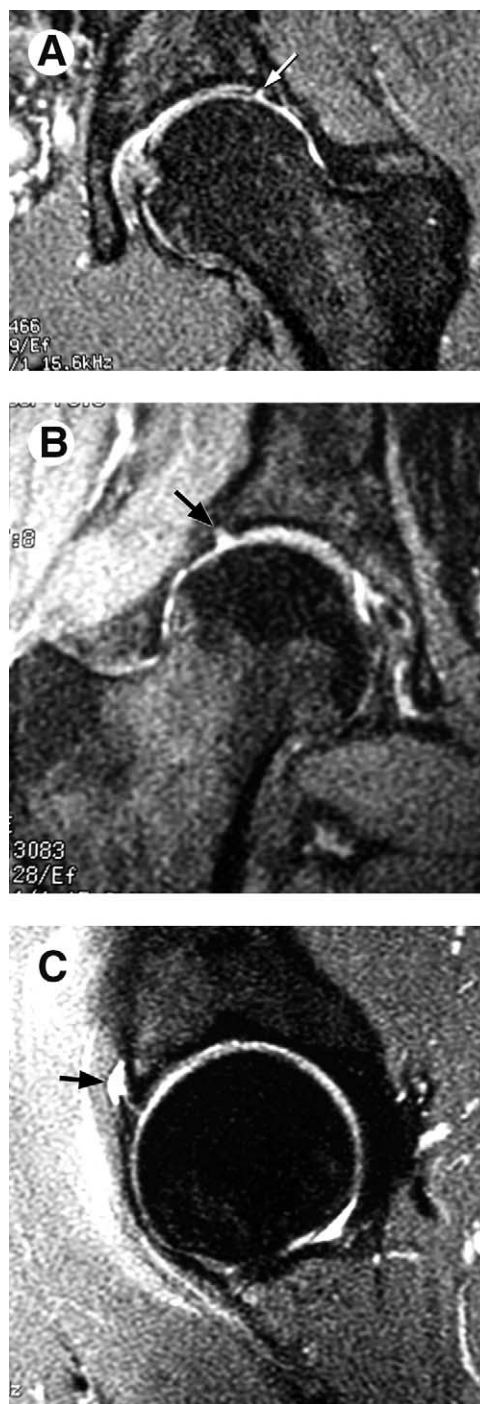

Figure 1 Three National Hockey League hockey players were referred, each with a 2-week history of hip pain after an injury on the ice. Each case showed MRI evidence of labral pathology (arrows). These cases were treated with 2 weeks of rest followed by a 2-week period of gradually resuming activities. Each of these athletes was able to return to competition and have continued to play for several seasons without needing surgery. (A) Coronal image of a left hip shows a lateral labral tear (arrow). (B) Coronal image of a right hip shows a lateral labral tear (arrow). (C) Sagittal image of a left hip shows an anterior labral tear with associated paralabral cyst (arrow). (Figure © J.W. Thomas Byrd.)

that abduction with external rotation, translates the femoral head anteriorly, exacerbating symptoms associated the anterior labral pathology or subtle instability. These maneuvers may normally be uncomfortable, so it is important to compare the asymptomatic to the symptomatic side. Most important is not simply whether the maneuver is uncomfortable, but whether it recreates the type of pain that the athlete experiences with activities. Sometimes, there may be an accompanying click or pop. These may be indicative of pathology but often occur in normal hips.

For longstanding conditions, athletes may secondarily develop extra-articular symptoms of tendinitis or bursitis or may simply have coexistent extra-articular pathology. A very useful test for distinguishing the intra-articular origin of symptoms is a fluoroscopically guided intra-articular injection of anesthetic. The hallmark is temporary alleviation of symptoms during the anesthetic effect. However, it is essential that the athlete be able to perform activities that will predictably create pain before the injection to substantiate the response to the anesthetic. If their symptoms are intermittent or unpredictable, then it is difficult to confirm that absence after the injection is solely attributable to the anesthesia. With the more recent technology of gadolinium arthrography combined with magnetic resonance imaging (MRI), always be certain to include anesthetic with the injection to gain this most useful diagnostic response.

Radiographs are an integral part of the assessment of hip injuries. This should include an anteroposterior (AP) film of the pelvis centered low to assess the hip joints and a frog lateral of the affected side. A properly centered pelvis film is essential to assess various radiologic measurements indicative of abnormal hip morphology, such as dysplasia or impingement. It also allows assessment of the surrounding areas and comparison of the asymptomatic hip to judge subtle radiographic asymmetries. The frog lateral, although not a true lateral of the joint but simply a lateral of the proximal femur, serves well as a routine screening film. False profile views and cross-table lateral radiographs may be necessary for further defining specific conditions.

MRI necessitates a high resolution study including a 1.5-T magnet with a surface coil to reasonably assess the intra-articular structures.⁵ Lesser quality studies (ie, small magnet or open scanner) are unreliable in assessing the joint other than obvious disease such as avascular necrosis. Conventional MRIs are getting better at discerning labral pathology but remain poor at detecting associated articular lesions. Often, indirect evidence of pathology may be the most reliable finding.⁶ On T2-weighted images, asymmetric effusion in a symptomatic hip is significant indirect evidence of pathology. Because of the low volume, noncompliant capsule, even small effusions are significant. Paralabral cysts are pathognomonic of labral pathology and subchondral cysts are highly indicative of associated articular damage.

Mechanism of Injury

The mechanism of injury can be as varied as the sports in which athletes participate. In general, hip disorders attribut-

able to a significant episode of trauma tend to respond better to arthroscopy.⁷ This is because, other than the damage because of trauma, the athlete usually has an otherwise healthy joint. Individuals who simply develop progressive onset of symptoms in absence of injury tend to experience a less complete response. This is because insidious onset of symptoms usually suggests either underlying disease or some predisposition to injury that cannot be fully reversed and may leave the joint vulnerable to further deterioration in the future. Even the presence of an acute injury such as a twisting episode, which is known to cause a tear of the acetabular labrum, may be more likely if the labrum was vulnerable to injury and may represent a less certain response to surgery. This vulnerability can be caused by abnormal labral morphology or underlying degeneration. Femoroacetabular impingement is increasingly recognized as a source of compressive lesions of the labrum.⁴ Conversely, the labrum may fail from excessive traction, such as in high-level tennis, in which the open stance creates extreme external rotation of the joint and anterior translation of the femoral head.

However, these broad generalizations must be tempered in the competitive athlete. Individuals who participate in contact and collision sports simply may not be able to recount which traumatic episode or series led to the onset of symptoms. Remember that significant intra-articular damage can occur from an episode without the athlete developing incapacitating pain. They may be able to continue to compete and subsequently undergo work up only when symptoms fail to resolve. Injury can occur from any contact or collision sport or sports involving forceful or repetitive twisting of the hip. The aging joint may also be more vulnerable. These parameters do not exclude many sports.

A particular entity has been identified associated with acute chondral damage.⁸ It is mostly encountered in physically fit young adult males. The characteristic feature is a lateral impact injury to the area of the trochanter (Fig. 2). Young adult males are apt to be participating in contact and collision activities in which this mechanism is frequent. With good body conditioning, they have little adipose tissue overlying the trochanter so much of the force of the blow is delivered directly to the bone. This force is then transferred unchecked into the hip joint, resulting in either shearing of the articular surface on the medial aspect of the femoral head at the tide mark or compression of the articular surface on the superior medial acetabulum, exceeding its threshold. The result is a full-thickness articular fragment from the femoral head or articular surface breakdown of the acetabulum, possibly with loose bodies, depending on the magnitude of acetabular chondral, or chondro-osseous cell death (Figs. 3 and 4). This mechanism is dependent on peak bone density as otherwise the force would result in fracture rather than delivery of the energy to the surface of the joint. The injury will usually result in immediate onset of symptoms but may not be disabling. It may be assessed as a groin pull, with workup ensuing only when symptoms fail to resolve.

Ice hockey is a sport that seems to present a particularly high prevalence of hip pathology. Hip flexibility is a premium consideration in this sport. The joint is subjected to violent

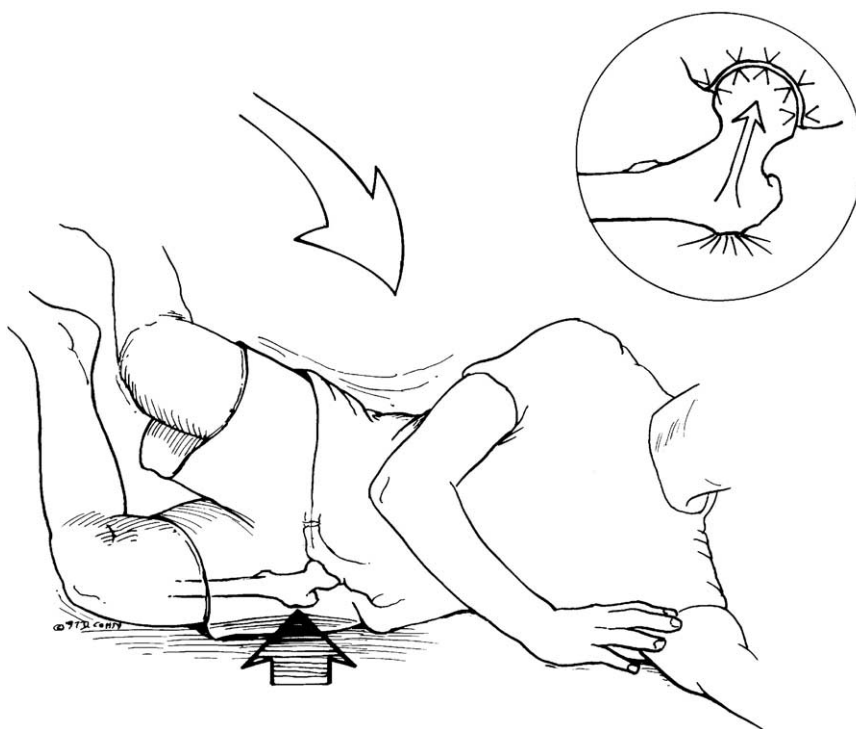


Figure 2 Fall results in direct blow to the greater trochanter, and, in absence of fracture, the force generated is transferred unchecked to the hip joint.

and repetitive torsional maneuvers and also subjected to relatively high-velocity impact loading. Thus, the labrum is susceptible to tearing from the twisting maneuvers, whereas the articular surface is vulnerable to impact injury. Often, acute episodes are simply superimposed on the cumulative effect of years of exposure (Fig. 1A-C).

Golf is another illustrative sport that seems to have a predilection for precipitating hip symptoms. It is not a contact or

collision sport, but the golf swing does incorporate a significant element of twisting on the hip joint. Additionally, it is a sport in which participants can compete with advancing age, even at the professional level. Thus, there is the greater susceptibility to injury of an aging hip as well as the cumulative

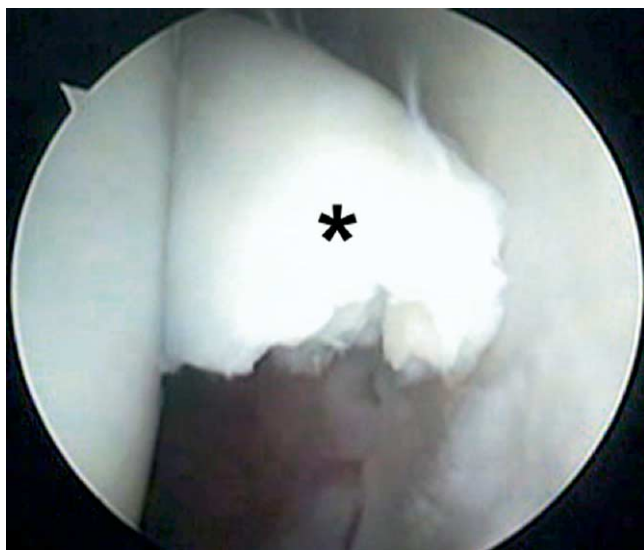

Figure 3 Arthroscopic view of the left hip of a 20-year-old collegiate basketball player shows an acute grade IV articular injury (asterisk) to the medial aspect of the femoral head. (Figure © J.W. Thomas Byrd.) (Color version of figure is available online.)

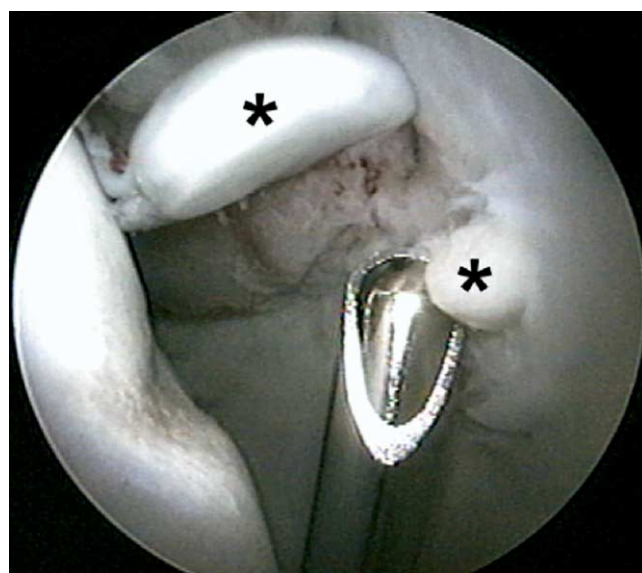


Figure 4 Arthroscopic view of the left hip of a 19-year-old man who sustained a direct lateral blow to the hip subsequently developing osteocartilaginous fragments (asterisks) within the superomedial aspect of the acetabulum. (Figure © J.W. Thomas Byrd.) (Color version of figure is available online.)

Table 2 Diagnoses For Hip Arthroscopy

Labral pathology (27)
Chondral damage (23)
Ligamentum teres damage (11)
Arthritic disorder (7)
Dysplasia (5)
Loose bodies (3)
Impinging osteophyte (2)
Avascular necrosis (1)
Synovitis (1)
Perthes disease (1)

effect of repetitive trauma over a prolonged career. Tennis shares many of these same attributes.

In a study of athletes undergoing arthroscopy, injury to the ligamentum teres was the third most common finding (Table 2).¹ Historically, rupture of the ligament is associated with hip dislocation. It has been recognized that injury can occur without dislocation, but this has been described only as case reports.⁹⁻¹² Disruption appears to be attributable to a twisting injury and is increasingly recognized as a source of intractable hip pain. In a study by this author of 23 cases of

traumatic injury to the ligamentum teres, 17 (74%) occurred without accompanying dislocation of the hip.¹³

Treatment

Arthroscopy has found a role in the treatment of numerous and varied forms of intra-articular pathology of the hip.^{14,15} The basic principles for accessing the joint have been well defined.¹⁶⁻²¹ It is important to follow these to perform the procedure as effectively as possible. Some cases will be more difficult than others. Thus, it is essential to assure that the procedure is performed with technical precision to make it as easy as possible. Accessing the joint for arthroscopy is not a remarkable technical accomplishment. More important is performing the procedure as atraumatically as possible.

Loose bodies can be extracted and arthroscopy offers an excellent alternative to arthrotomy, previously indicated for this condition (Fig. 5).²²⁻²⁴ Most problematic loose bodies reside in the intra-articular compartment and are addressed with standard arthroscopic methods. However, many may remain hidden in the peripheral compartment and later become troublesome. Thus, arthroscopy to address symptom-

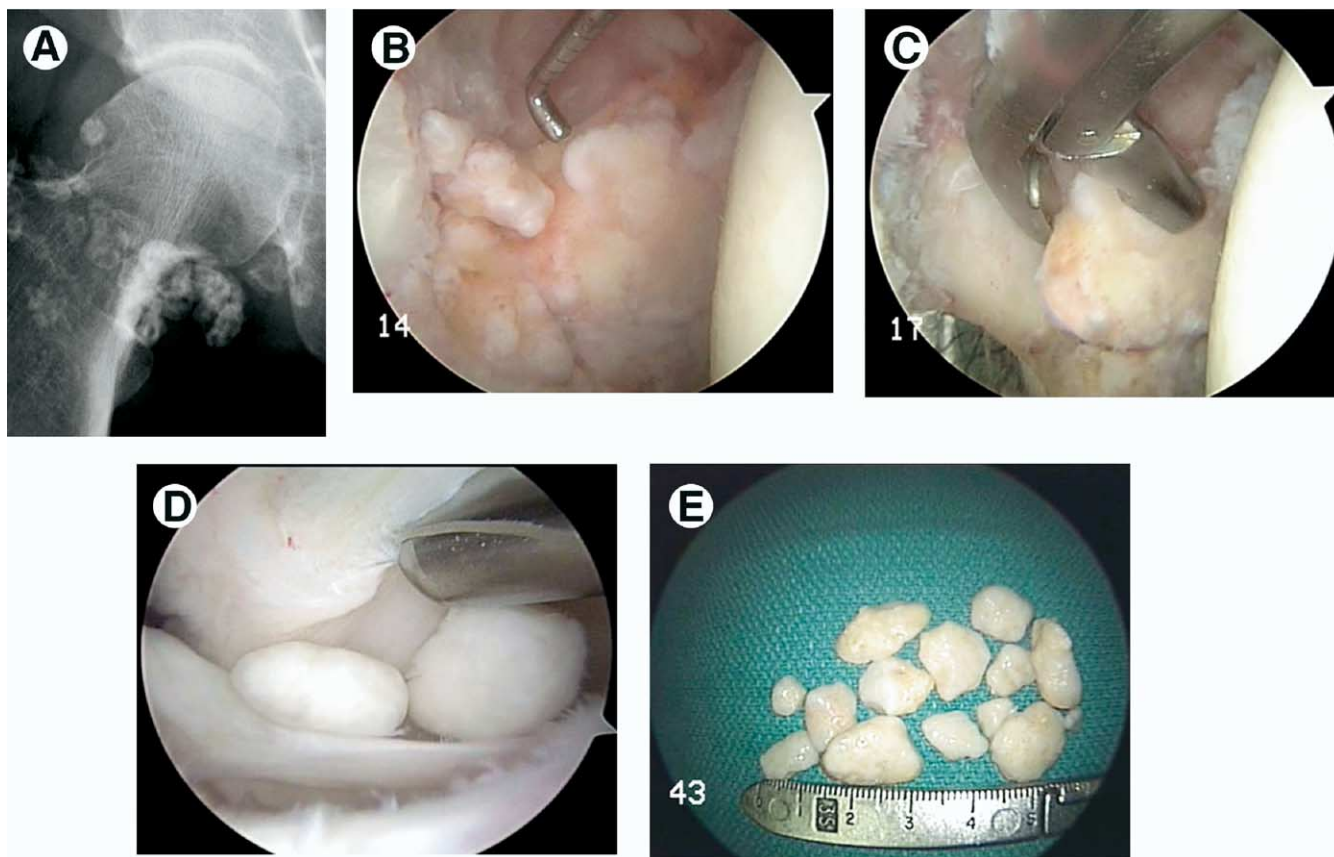


Figure 5 A 54-year-old Hall of Fame baseball player with a several-year history of insidious onset, progressively worsening mechanical right hip pain. (A) An AP radiograph shows evidence of synovial chondromatosis as well as secondary degenerative changes. (B) Arthroscopic view of the intra-articular compartment shows numerous lesions obliterating the acetabular fossa. (C) These are morselized and excised. (D) The peripheral compartment reveals more free-floating loose bodies. (E) Whole fragments removed from the peripheral compartment. (Figure © J.W. Thomas Byrd.) (Color version of figure is available online.)

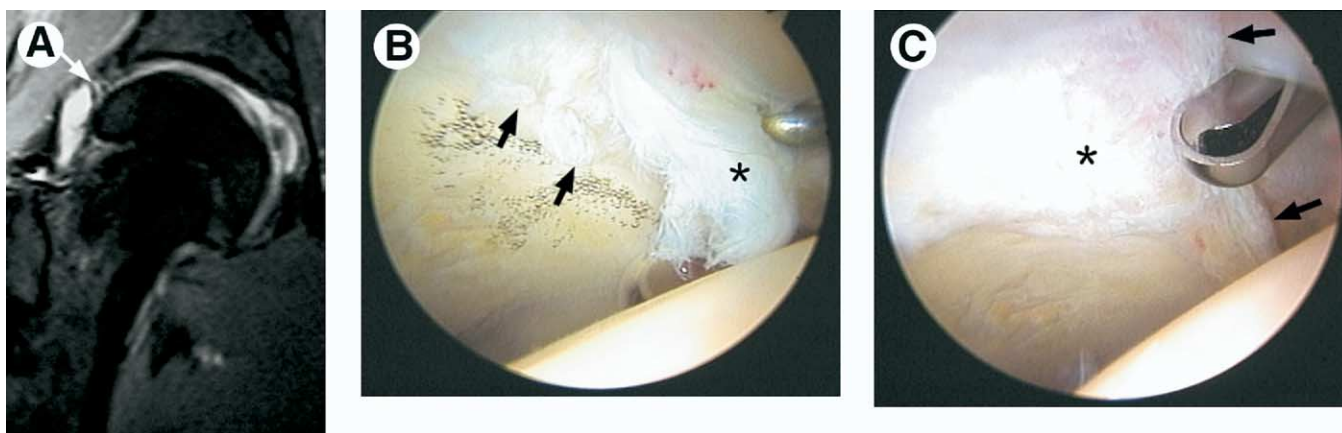


Figure 6 A 25-year-old top-ranked professional tennis player sustained a twisting injury to his right hip. (A) Coronal MRI shows evidence of labral pathology (arrow). (B) Arthroscopy reveals extensive tearing of the anterior labrum (asterisk) as well as an adjoining area of grade III articular fragmentation (arrows). (C) The labral tear has been resected to a stable rim (arrows), and chondroplasty of the grade III articular damage (asterisk) is being performed. (Figure © J.W. Thomas Byrd.) (Color version of figure is available online.)

atic fragments must include both the intra-articular and peripheral joint.²⁵ Many can be debrided with shavers or flushed through large diameter cannulas. Large ones can sometimes be morselized and removed piecemeal. However, often fragments may be too large to be removed through a cannula system and must be removed freehand with sturdy graspers. Once a portal tract has been developed, these larger graspers can be passed along the remaining tract into the joint in a freehand fashion. Make sure to enlarge the capsular incision with an arthroscopic knife and the skin incision so that, as the fragment is retrieved, it will not be lost in the tissues either at the capsule or subcutaneous level.

Traumatic labral tears may respond remarkably well to arthroscopic debridement (Fig. 6).²⁶⁻³⁰ However, at arthroscopy be especially cognizant of any underlying degeneration that may have predisposed to the acute tear. There will often be accompanying articular damage, and the extent of this may be a significant determinant on the eventual response to debridement (Fig. 7). Also, with the evolving understanding of femoroacetabular impingement and its role in the development of labral and chondral damage, it is important to make a careful radiographic assessment of accompanying bony lesions of the anterior acetabulum or femoral head that may require reshaping (Fig. 8).³¹

Labral tears can be adequately accessed through the 3 standard portals. Similar to a meniscus in the knee, the task is to remove unstable and diseased labrum creating a stable transition to retained healthy tissue. The most difficult aspect is creating the stable transition zone. Thermal devices have been quite useful at ablating unstable tissue adjacent to the healthy portion of the labrum. Caution is necessary because of the concerns regarding depth of heat penetration, but with judicious use, these devices have been exceptionally useful for precise labral debridement despite the constraints created by the architecture of the joint.

The natural evolution in arthroscopic management of labral pathology is from debridement to repair. Current meth-

ods of acetabular labral repair are in their infancy. A few have been attempted with mixed results. Reliable techniques remain to be developed but are probably not far off. In addition to technical advancements, there is much that remains regarding our understanding of labral morphology and pathophysiology. There is considerable variation in the normal appearance of the labrum including a labral cleft at the articular labral junction, which can be quite large.²¹ It is important to distinguish this from a traumatic detachment which can also occur. Additionally, many labral tears, even in the presence of a significant history of injury, seem to occur because of some underlying predisposition or degeneration. Under these circumstances, even with reliable techniques, repair of a degenerated or morphologically vulnerable labrum would unlikely be successful.

Chondroplasty can be effectively performed for lesions of both the acetabular and femoral surfaces. Curved shaver blades are helpful for negotiating the constraints created by the convex surface of the femoral head. Because of limitations of maneuverability, thermal devices have again been especially helpful in ablating unstable fragments. However, cautious and judicious use around articular surface is even more important because of potential injury to surviving chondrocytes.

Microfracture of select grade IV articular lesions has been beneficial (Fig. 7).³⁰ As with other joints, it is best indicated for focal lesions with healthy surrounding articular surface. The lesion most amenable to this process is encountered in the lateral aspect of the acetabulum. This is followed by 8 to 10 weeks of protected weight bearing to neutralize the forces across the hip joint while emphasizing range of motion. By using this protocol, among a cohort of 24 patients, 86% showed a successful outcome at 2- to 5-year follow-up.³²

Injury to the ligamentum teres is increasingly recognized as a source of hip pain in athletes (Fig. 9).¹ The disrupted fibers catch within the joint and can be quite symptomatic. This disruption may be the result of trauma, degeneration, or

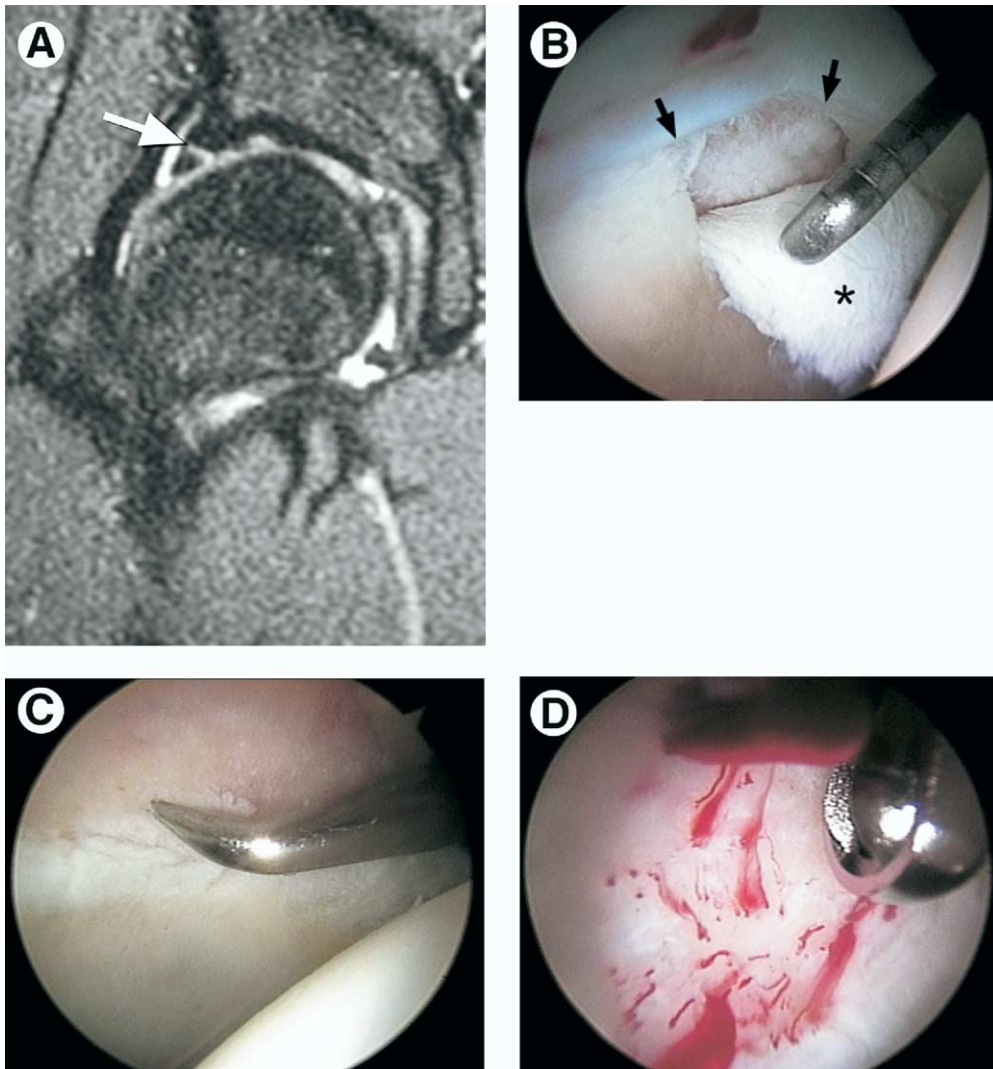


Figure 7 A 23-year-old elite professional tennis player sustained an injury to his right hip. (A) Coronal MRI shows evidence of labral pathology (arrow). (B) Arthroscopy reveals the labral tear (arrows) but also an area of adjoining grade IV articular loss (asterisk). (C) Microfracture of the exposed subchondral bone is performed. (D) Occluding the inflow of fluid confirms vascular access through the areas of perforation. The athlete was maintained on a protected weight-bearing status emphasizing range of motion for 10 weeks with return to competition at 3 and a half months. (Figure © J.W. Thomas Byrd.) (Color version of figure is available online.)

a combination of both.³³ The tear may be partial or complete with the goal of treatment being to debride the entrapping, disrupted fibers. A recent report by these authors documented excellent success in the arthroscopic management of traumatic lesions of the ligamentum teres. The average improvement was 47 points (100-point modified Harris Hip score system) with 93% showing marked (>20 points) improvement.¹³

The acetabular attachment of the ligamentum teres is situated posteriorly at the inferior margin of the acetabular fossa and attaches on the femoral head at the fovea capitis. The disrupted portion of the ligament is avascular, but the fat pad and synovium contained in the superior portion of the fossa can be quite vascular. Debridement is facilitated by a complement of curved shaver blades and a thermal device. The disrupted portion of the ligament is unstable and delivered

by suction into the shaver. A thermal device can also ablate tissue while maintaining hemostasis within the vascular pulvinar.

Access to this inferomedial portion of the joint is best accomplished from the anterior portal. External rotation of the hip also helps in delivering the ligament to the shaver brought in anteriorly. The most posterior portion of the fossa and the acetabular attachment of the ligament may be best accessed from the posterolateral portal. Indiscriminate debridement of the ligamentum teres should be avoided because of its potential contribution to the vascularity of the femoral head.

Primary synovial disease may be encountered in athletes, but more often synovial proliferation occurs in response to other intra-articular pathology. Synovitis may be diffuse, encompassing the lining of the joint capsule or be focal, ema-

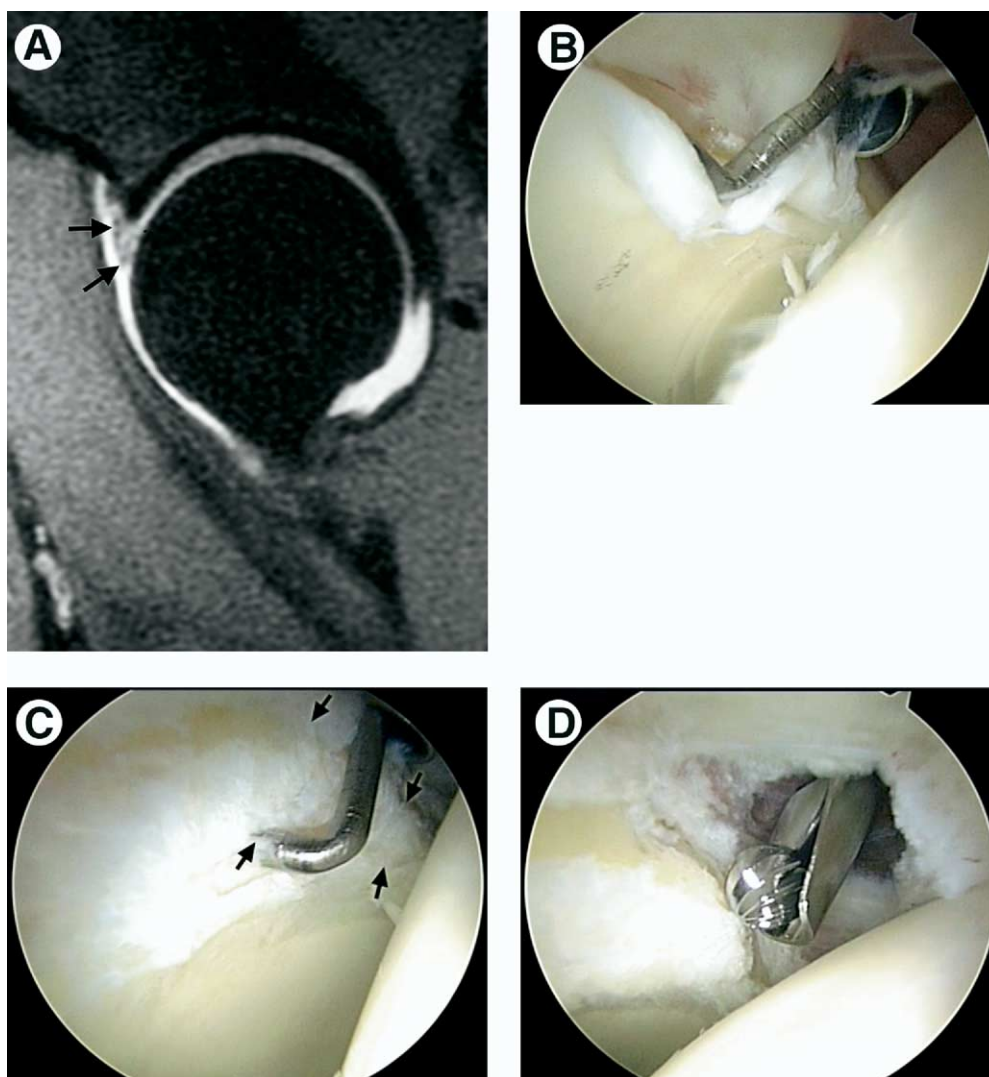


Figure 8 A 16-year-old high school football player develops acute onset of right hip pain doing squats. (A) Sagittal image magnetic resonance arthrogram shows a macerated anterior labrum (arrows). (B) Viewing from the anterolateral portal, a macerated tear of the anterior labrum is probed along with articular delamination at its junction with the labrum. (C) The damaged anterior labrum has been excised, revealing an overhanging lip of impinging bone from the anterior acetabulum. (D) Excision of the impinging portion of the acetabulum (acetabuloplasty) is performed with a burr. (Figure © J.W. Thomas Byrd.) (Color version of figure is available online.)

nating from the pulvinar of the acetabular fossa. Focal lesions within the fossa may be dense and fibrotic or exhibit proliferative villous characteristics. Presumably, because of entrapment within the joint, these lesions can be quite painful and respond remarkably well to simple debridement. Although a complete synovectomy cannot be performed, a generous subtotal synovectomy can be performed. Enlarging the capsular incisions with an arthroscopic knife improves maneuverability within the intra-articular portion of the joint. For most synovial disease, arthroscopy of the peripheral compartment is necessary to adequately resect the diseased tissue.^{25,31}

In the presence of clinical evidence of arthritis, there will be arthroscopic evidence of various pathology including free fragments, labral tearing, articular damage, and synovial disease. With a meticulous systematic approach, each compo-

nent can be addressed arthroscopically. Ultimately, with a well performed procedure, the response to treatment will be mostly dictated by the extent of pathology, much of which cannot be reversed.³⁴⁻³⁷

Posttraumatic impinging bone fragments, occasionally encountered in an active athletic population, may respond well to arthroscopic excision.^{14,38} Degenerative osteophytes rarely benefit from arthroscopic excision because the symptoms are usually more associated with the extent of joint deterioration and not simply the radiographically evident osteophytes that secondarily form. However, the posttraumatic type may impinge on the joint causing pain and blocking motion. These fragments are often extracapsular and require a capsulotomy extending the dissection outside the joint for excision (Fig. 10). This necessitates thorough knowledge and careful orientation of the extra-articular anatomy and excellent visu-

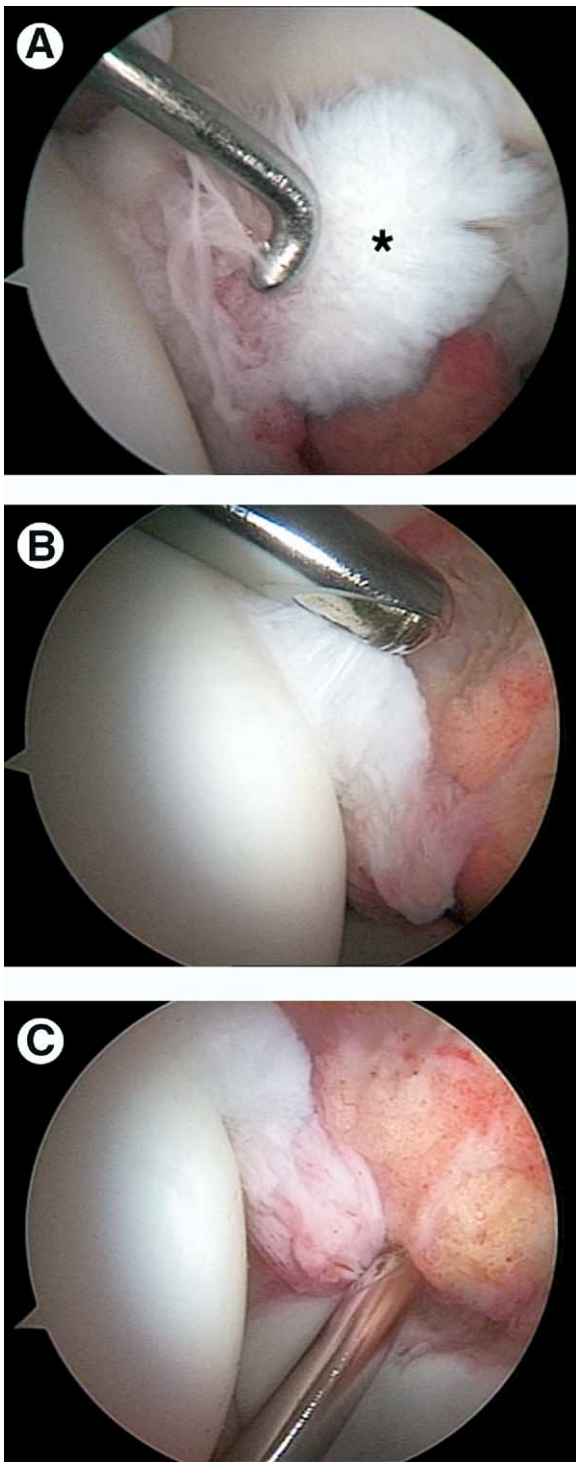


Figure 9 A 16-year-old cheerleader has a 2-year history of catching and locking of the left hip after a twisting injury. (A) Arthroscopic view from the anterolateral portal reveals disruption of the ligamentum teres (asterisk). (B) Debridement is begun with a synovial resector introduced from the anterior portal. (C) The acetabular attachment of the ligamentum teres in the posterior aspect of the fossa is addressed from the posterolateral portal. (Figure © J.W. Thomas Byrd.) (Color version of figure is available online.)

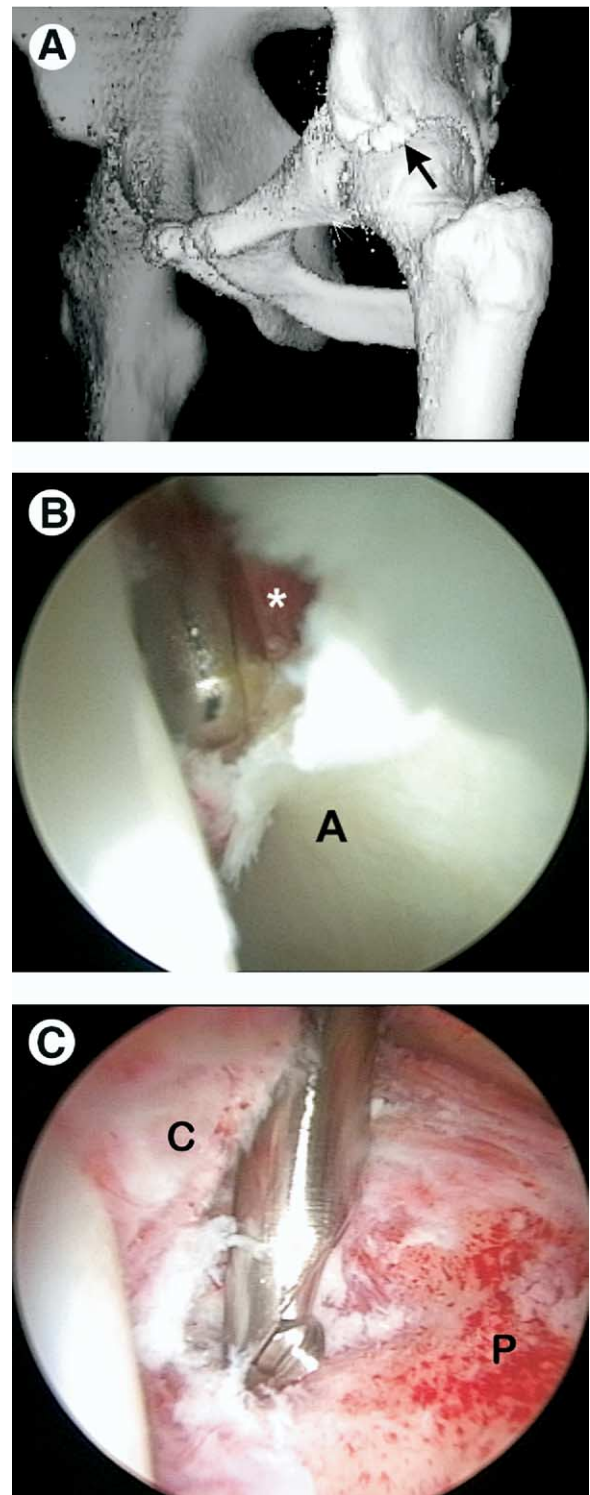


Figure 10 An 18-year-old high school football player sustained an avulsion fracture of the left anterior inferior iliac spine. (A) A 3-dimensional computed tomography scan shows the avulsed fragment (arrow), which ossified, creating an impinging painful block to flexion and internal rotation. (B) Viewing from the anterolateral portal, a capsular window is created, exposing the osteophyte (asterisk) anterior to the acetabulum (A). (C) The anterior capsule (C) has been completely released allowing resection of the fragment along the anterior column of the pelvis (P). Postoperatively, the patient regained full range of motion with resolution of his pain. (Figure © J.W. Thomas Byrd.) (Color version of figure is available online.)

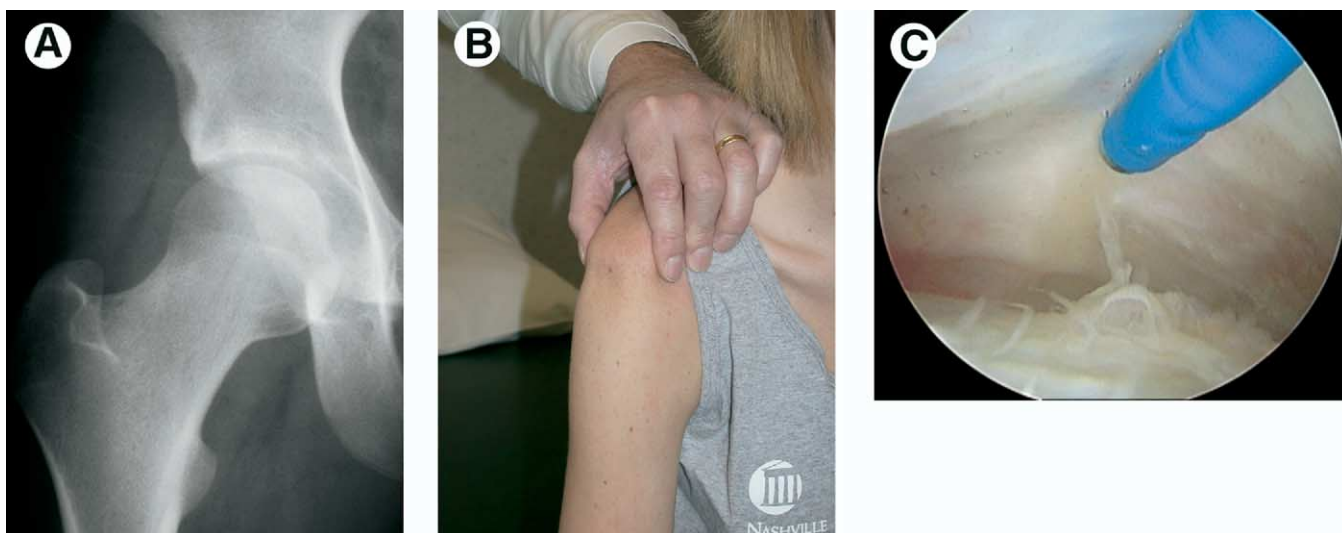


Figure 11 A 19-year-old woman had undergone two previous arthroscopic procedures on her right hip for reported lesions of the ligamentum teres. After each procedure, she developed recurrent symptoms of “giving way.” (A) Radiographs revealed normal joint geometry. (B) She was noted to have severe diffuse physiologic laxity best characterized by a markedly positive sulcus sign. (C) With objective evidence of laxity and subjective symptoms of instability, an arthroscopic thermal capsulorrhaphy was performed, accessing the redundant anterior capsule from the peripheral compartment. Modulation of the capsular response was controlled by a hip spica brace for 8 weeks postoperatively with a successful outcome. (Figure © J.W. Thomas Byrd.) (Color version of figure is available online.)

alization at all times during the procedure. In general, the dissection should stay directly on the bone fragments and avoid straying into the surrounding soft tissues. Various techniques aid in maintaining optimal visualization. A high-flow pump is especially helpful, maintaining a high-flow rate without excessive pressure, which would worsen extravasation. Hypotensive anesthesia, placing epinephrine in the arthroscopic fluid, and electrocautery or other thermal device for hemostasis all aid in visualization for effectively performing the excision.

Hip instability can occur but is much less common than seen in the shoulder. There are several reasons but, most principally, this is because of the inherent stability provided by the constrained ball and socket bony architecture of the joint. Also, the labrum is not as critical to stability of the hip as it is in the shoulder because there is no true capsulolabral complex. On the acetabular side, the capsule attaches directly to the bone, separate from the acetabular labrum.³⁹ An entrapped labrum has been reported as a cause of an irreducible posterior dislocation and a Bankart-type detachment of the posterior labrum has been identified as the cause of recurrent posterior instability.^{40,41} These circumstances have only rarely been reported but may be recognized with increasing frequency as our understanding and intervention of hip injuries evolves.

Instability may occur simply because of an incompetent capsule. This is seen in hyperlaxity states and less often encountered in athletics. The most common cause is a collagen vascular disorder such as Ehlers-Danlos syndrome. With normal joint geometry, thermal capsular shrinkage has continued to meet with successful results (Fig. 11). If subluxation or symptomatic instability is caused by a dysplastic joint,

it is likely that bony correction for containment is necessary to achieve stability.

Based on this author’s observations, we have found that posterior instability is associated with macrotrauma. This is because of the characteristic mechanisms of injury, including dashboard injuries and axial loading of the flexed hip encountered in collision sports. Atraumatic instability, or instability because of repetitive microtrauma, is anterior and develops when the normally occurring anterior translation of the femoral head exceeds the physiologic threshold and becomes pathological. Symptoms may be caused by primary instability or secondary intra-articular damage or a combination of both.

Rehabilitation

As with any joint, physical therapy is an integral part of facilitating and optimizing recovery after arthroscopic surgery of the hip. This is a functional progression based on the type of pathology, the procedure performed, and the eventual goals of the athlete.⁴²⁻⁴⁴ An early goal is to normalize the gait pattern based on symptoms and motor control. Crutches are often beneficial for 4 to 5 days until no noticeable limp is present. For arthritic conditions, crutches may be useful for several weeks while symptoms are subsiding. For microfracture cases, a strict protected weight-bearing status is maintained for 8 to 10 weeks to neutralize the forces across the joint surfaces while emphasizing motion to stimulate a potential fibrocartilaginous healing response.

In general, range of motion is pushed only to tolerance. Unlike the knee or the shoulder, some reduced range of motion is often well tolerated by athletes and may be unno-

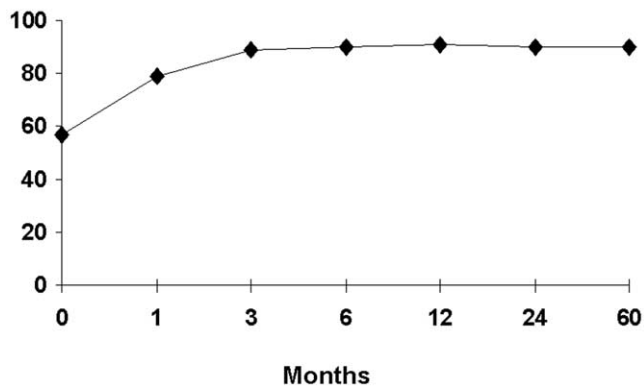


Figure 12 Average modified Harris hip scores among athletes at various intervals of follow-up. (Figure © J.W. Thomas Byrd.)

ticed. Functionally, individuals can compensate very effectively for diminished mobility. In fact, pushing the end ranges of motion may be counterproductive and only serve to exacerbate the athlete’s symptoms. However, there are some circumstances in which reduced motion is a functional problem, precipitating treatment and can be improved with arthroscopic debridement. Thus, range of motion may be a principal focus of the rehabilitation process, such as with femoroacetabular impingement and adhesive capsulitis.⁴⁵

Closed chain, low impact exercises are gradually transitioned to a functional rehabilitation program simulating the athlete’s eventual activities in a controlled environment. Typically, 1 month is necessary to recuperate from the acute aspects of surgical intervention. Gradual resumption of unrestricted activities generally progresses at 2 to 3 months, depending on the nature of the pathology and the athlete’s functional response.

Athletes with arthritic conditions can be expected to recover more slowly and less completely. Microfracture cases necessitate approximately three months of deliberate restrictions. Capsulorrhaphy for symptomatic instability also requires a period of immobilization, usually in a hip spica brace for a period of 6 to 8 weeks with cautious resumption of activities to avoid recurrent problems.

Results

In a study by Byrd and Jones¹ of 42 athletes, the average improvement using a modified Harris hip rating system (100-point maximum) was 35 points (preoperatively 57; postoperatively 92). Ninety-three percent showed at least 10 points of improvement. Also, of those questioned, 76% returned to their sport symptom free and unrestricted or at least at an increased level of performance, whereas 18% either chose not to return or were unable to return to their primary sport.

After understanding the potential benefits of an arthroscopic procedure, the next issue of paramount importance among athletes is how quickly they will recover. According to the same study, the greatest improvement (67%) was noted after the first month. Maximal improvement was achieved by

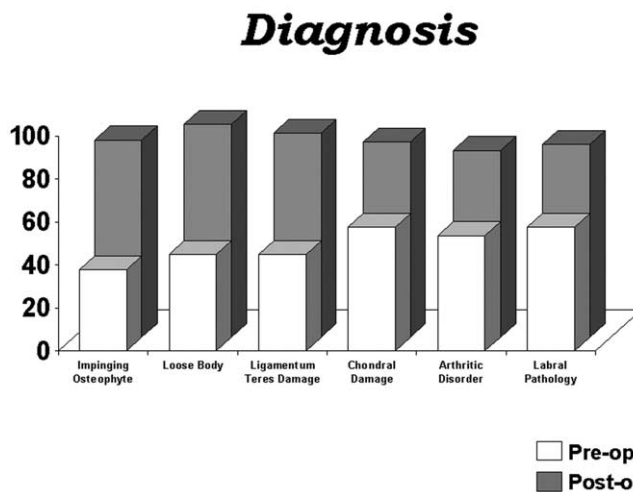


Figure 13 Results based on specific diagnoses. (Figure © J.W. Thomas Byrd.)

3 months, and these results were maintained among those athletes with 5-year follow-up (Fig. 12).

Among athletes, the best results have been seen for impinging osteophytes, loose bodies, and rupture of the ligamentum teres (Fig. 13). Impinging osteophytes are uncommon, but when recognized, the structural problem can be corrected, thus often resulting in pronounced symptomatic improvement. Loose bodies have traditionally been recognized as the clearest indication for arthroscopy. Predictable results have been further confirmed in the athletic population. Rupture of the ligamentum teres is an entity that has infrequently been reported in the literature. A propensity for this injury has been identified among athletes, being the third leading diagnosis, and responds remarkably well to arthroscopic debridement. More average results have been reported for labral tearing and chondral injury. The results are poor in the presence of clinical evidence of arthritis, but those pa-

Onset of Symptoms

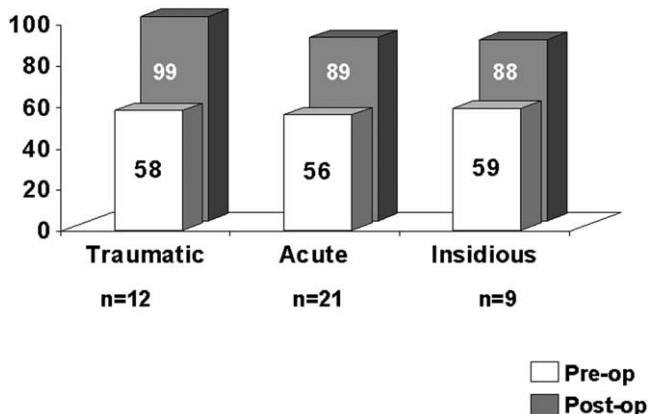


Figure 14 Results based on the onset of symptoms. (Figure © J.W. Thomas Byrd.)

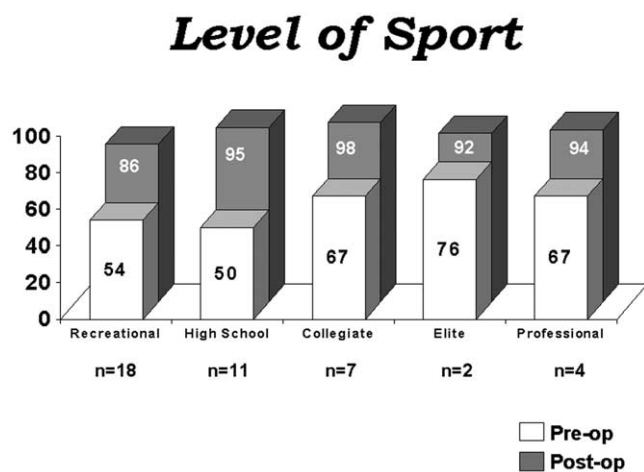


Figure 15 Results based on level of sport. (Figure © J.W. Thomas Byrd.)

tients undergoing microfracture fared better than with simple chondroplasty.

The nature of the onset of symptoms seems to at least partially influence the results. Those with a specific history of a significant traumatic event fare the best (Fig. 14), whereas those of insidious onset did the worst. Patients with acute onset of symptoms fared only slightly better than those with an insidious onset, suggesting that, even in the presence of a modest explainable injury, some type of predisposition should be suspected and the results of arthroscopy may be less certain.

Among the reported group of athletes, one third competed at the collegiate, elite, or professional level (Fig. 15). These groups had a higher baseline preoperative score than the recreational and high school athletes. This suggests that these athletes are functioning near the physiologic limits of the body and at a level in which small deficits may significantly influence the athlete's performance.

Conclusions

The indications for hip arthroscopy have been well established. The results among athletes appear to be favorable and, in fact, are somewhat better than those reported among a general population.

Intra-articular disorders in athletes may go unrecognized for a protracted period of time, most commonly being diagnosed as a strain. With an increasing awareness of these intra-articular problems and the intensity of services often available to athletes, joint injuries are now being diagnosed earlier. However, this emphasis for earlier diagnosis must be tempered. It is still likely that extra-articular injuries vastly outnumber injuries within the joint and thus one should avoid the temptation for an extensive intra-articular workup for every simple muscle strain. Also, it is unknown whether early diagnosis necessitates early intervention. There is much that is not understood regarding the natural history of some of these intra-articular disorders. Thus, although perhaps it is difficult to say that a labral lesion identified by MRI will heal,

it is uncertain how many of these may become clinically quiescent and asymptomatic or whether some of the signal changes evident on imaging may be caused by remote trauma that had previously become silent.

Nonetheless, arthroscopy has defined various sources of intra-articular hip pathology. In many cases, operative arthroscopy may result in significant symptomatic improvement. For some, arthroscopy offers a distinct advantage over traditional open techniques, but, for many, arthroscopy now offers a method of treatment where none existed before.

References

- Byrd JWT, Jones KS: Hip arthroscopy in athletes. *Clin Sports Med* 20:749-762, 2001
- Byrd JWT: Investigation of the symptomatic hip: Physical examination, in Byrd JWT (ed): *Operative Hip Arthroscopy*. New York, NY, Thieme, 1998, pp 25-41
- O'Leary JA, Berend K, Vail TP: The relationship between diagnosis and outcome in arthroscopy of the hip. *Arthroscopy* 17:181-188, 2001
- Ganz R, Parvizi J, Beck M, et al: Femoroacetabular impingement: a cause for osteoarthritis of the hip. *Clin Orthop* 417:112-120, 2003
- Erb RE: Current concepts in imaging the adult hip. *Clin Sports Med* 20:661-696, 2001
- Byrd JWT, Jones KS: Diagnostic accuracy of clinical assessment, MRI, MRA, and intraarticular injection in hip arthroscopy patients. *Am J Sports Med* 32:1668-1674, 2004
- Byrd JWT, Jones KS: Prospective analysis of hip arthroscopy. *Arthroscopy* 16:578-587, 2000
- Byrd JWT: Lateral impact injury: A source of occult hip pathology. *Clin Sports Med* 20:801-816, 2001
- Delcamp DD, Klarren HE, VanMeerdevoort HFP: Traumatic avulsion of the ligamentum teres without dislocation of the hip. *J Bone Joint Surg* 70A:933-935, 1988
- Barrett IR, Goldert JA: Avulsion fracture of the ligamentum teres in a child. A case report. *J Bone Joint Surg* 71A:438-439, 1989
- Ebrahim NA, Salvolaie ER, Fenton PJ, et al: Calcified ligamentum teres mimicking entrapped intraarticular bony fragments in a patient with acetabular fracture. *J Orthop Trauma* 5:376-378, 1991
- Kashiwagi N, Suzuki S, Seto Y: Arthroscopic treatment for traumatic hip dislocation with avulsion fracture of the ligamentum teres. *Arthroscopy* 17:67-69, 2001
- Byrd JWT, Jones KS: Traumatic rupture of the ligamentum teres as a source of hip pain. *Arthroscopy* 20:385-391, 2004
- Byrd JWT: Indications and contraindications, in Byrd JWT (ed): *Operative Hip Arthroscopy*. New York, NY, Thieme, 1998, p 7-24
- Sampson TG, Glick JM: Indications and surgical treatment of hip pathology, in McGinty J, Caspari R, Jackson R, et al (eds): *Operative Arthroscopy* (ed 2). New York, NY, Lippincott-Raven, 1995, pp 1067-1078
- Byrd JWT: Hip arthroscopy utilizing the supine position. *Arthroscopy* 10:275-280, 1994
- Byrd JWT: The supine position, in Byrd JWT (ed): *Operative Hip Arthroscopy*. New York, NY, Thieme, 1998, pp 123-138
- Glick JM, Sampson TG: Hip arthroscopy by the lateral approach, in McGinty J, Caspari R, Jackson R, et al (eds): *Operative Arthroscopy* (ed 2). New York, NY, Raven Press, Ltd., 1995, pp 1079-1090
- Byrd JWT: Arthroscopy of the hip and applications: supine position, in Chow JC (ed): *Advanced Arthroscopy*. New York, NY, Springer-Verlag, 2000, pp 293-321
- Sampson TG, Farjo L: Hip arthroscopy by the lateral approach, in Byrd, JWT (ed): *Operative Hip Arthroscopy*. New York, NY, Thieme, 1998, pp 105-122
- Byrd JWT: Operative hip arthroscopy (video). New York, NY, Thieme, 1998
- Byrd JWT: Hip arthroscopy for post-traumatic loose fragments in the young active adult: Three case reports. *Clin Sport Med* 6:129-134, 1996
- McCarthy JC, Bono JV, Wardell S: Is there a treatment for synovial chondromatosis of the hip joint? *Arthroscopy* 13:409-410, 1997

24. Medlock V, Rathjen KE, Montgomery JB: Hip arthroscopy for late sequelae of Perthes Disease. *Arthroscopy* 15:552-553, 1999
25. Dienst M, Gödde S, Seil R, Hammer D, Kohn D: Hip arthroscopy without traction: In vivo anatomy of the peripheral hip joint cavity. *Arthroscopy* 17:924-931, 2001
26. Byrd JWT: Labral lesions: An elusive source of hip pain: case reports and review of the literature. *Arthroscopy* 12:603-612, 1996
27. Lage LA, Patel JV, Villar RN: The acetabular labral tear; An arthroscopic classification. *Arthroscopy* 12:269-272, 1996
28. Farjo LA, Glick JM, Sampson TG: Hip arthroscopy for acetabular labrum tears. *Arthroscopy* 13:409, 1997
29. Santori N, Villar RN: Acetabular labral tears: result of arthroscopic partial limbectomy. *Arthroscopy* 16:11-15, 2000
30. Byrd JWT, Jones KS: Osteoarthritis caused by an inverted acetabular labrum: Radiographic diagnosis and arthroscopic treatment. *Arthroscopy* 18:741-747, 2002
31. Byrd JWT: Hip arthroscopy: Evolving frontiers. *Oper Tech Sports Med* 14:58-67, 2004
32. Byrd JWT, Jones KS: Microfracture for grade IV chondral lesions of the hip. Proceedings of AANA 23rd Annual Meeting, Orlando, FL, April 25, 2004. *Arthroscopy* 20:41, 2004 (abstr)
33. Gray AJR, Villar RN: The ligamentum teres of the hip: an arthroscopic classification of its pathology. *Arthroscopy* 13:575-578, 1997
34. Farjo LA, Glick JM, Sampson TG: Hip arthroscopy for degenerative joint disease. *Arthroscopy* 14:435, 1998
35. Villar RN: Arthroscopic debridement of the hip: A minimally invasive approach to osteoarthritis. *J Bone Joint Surg* 73-B:170-171, 1991 (suppl 2)
36. Santori N, Villar RN: Arthroscopic findings in the initial stages of hip osteoarthritis. *Orthopedics* 22:405-409, 1999
37. Byrd JWT, Jones KS: Prospective analysis of hip arthroscopy with five year follow up. Presented at AAOS 69th Annual Meeting, Dallas, TX, February 14, 2002
38. Byrd JWT: Arthroscopy of select hip lesions, in Byrd JWT (ed): *Operative Hip Arthroscopy*. New York, NY, Thieme, 1998, pp 153-170
39. Seldes RM, Tan V, Hunt J, et al: Anatomy, histologic features, and vascularity of the adult acetabular labrum. *Clin Orthop* 382:232-240, 2001
40. Paterson I: The torn acetabular labrum: A block to reduction of a dislocated hip. *J Bone Joint Surg* 39B:306-309, 1957
41. Dameron TB: Bucket-handle tear of acetabular labrum accompanying posterior dislocation of the hip. *J Bone Joint Surg* 41A:131-134, 1959
42. Griffin KM, Henry CO, Byrd JWT: Rehabilitation after hip arthroscopy. *J Sport Rehabil* 9:77-88, 2000
43. Griffin KM, Henry CO, Byrd JWT: Rehabilitation, in Byrd JWT (ed): *Operative Hip Arthroscopy*. New York, NY, Thieme, 1998, pp 177-202
44. Henry C, Middleton K, Byrd JWT: Hip rehabilitation following arthroscopy, IOI Theater, AAOS Annual Meeting, Orlando, FL, February 16-21, 1995
45. Byrd JWT, Jones KS: Adhesive capsulitis of the hip. *Arthroscopy* 20:15-16, 2004